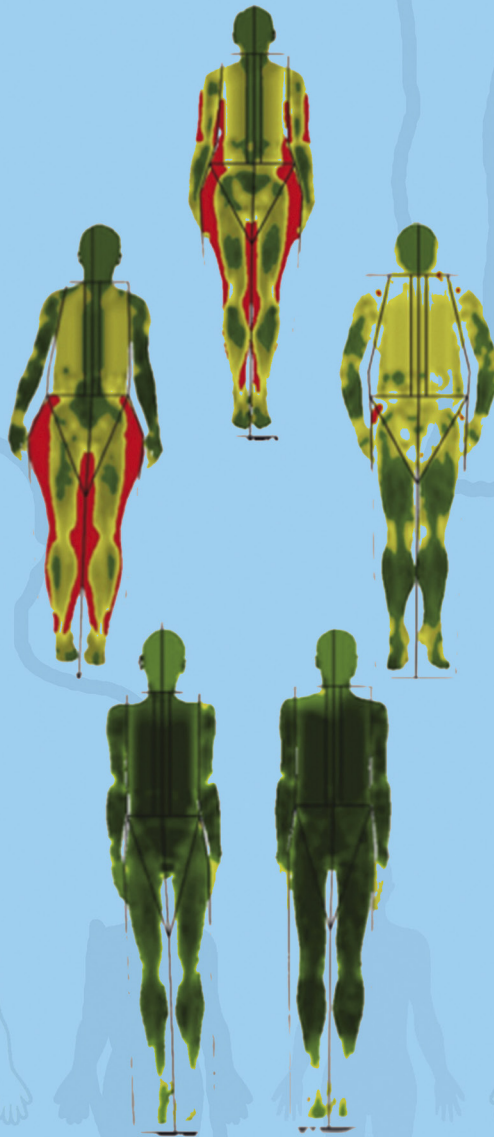


# Practical Guidelines for the Diagnosis and Treatment of Infrequent Lipodystrophies



David Araújo-Vilar  
Sofía Sánchez-Iglesias  
Cristina Guillín-Amarelle  
Antia Fernández-Pombo

Practical Guidelines  
for the Diagnosis and Treatment  
of Infrequent Lipodystrophies



**Title:** Practical Guidelines for the Diagnosis and Treatment of Infrequent Lipodystrophies.

**Authors:** David Araújo-Vilar, Sofía Sánchez-Iglesias, Cristina Guillín-Amarelle, Antía Fernández-Pombo.

**Publishers:** AELIP © 2020, 2nd edition.

**Editors:** Naca Eulalia Pérez de Tudela Cánovas, Juan Carrión Tudela, David Araújo-Vilar, José Jerez Ruiz.

**Design and layout:** Luis Silvestre.

**ISBN:** 978-84-09-25567-2.

**Legal deposit:** MU-1004-2020.

*Printed in Totana by Gráficas Hermanos Romero.*

**To Celia**  
In memoriam





**David Araújo-Vilar** is a professor of Medicine at the University of Santiago de Compostela and a consultant physician in Endocrinology and Nutrition at the University Hospital Complex of Santiago de Compostela (CHUS). Since 2003, his clinical and research activity has been focused on infrequent lipodystrophic syndromes and he is currently one of the most internationally distinguished experts in these diseases.

He is the director of the UETeM-Molecular Pathology Group at the Center for Research in Molecular Medicine and Chronic Diseases (CiMUS) of the University of Santiago de Compostela and is the director of the Lipodystrophy Unit of the Endocrinology Division of the CHUS.

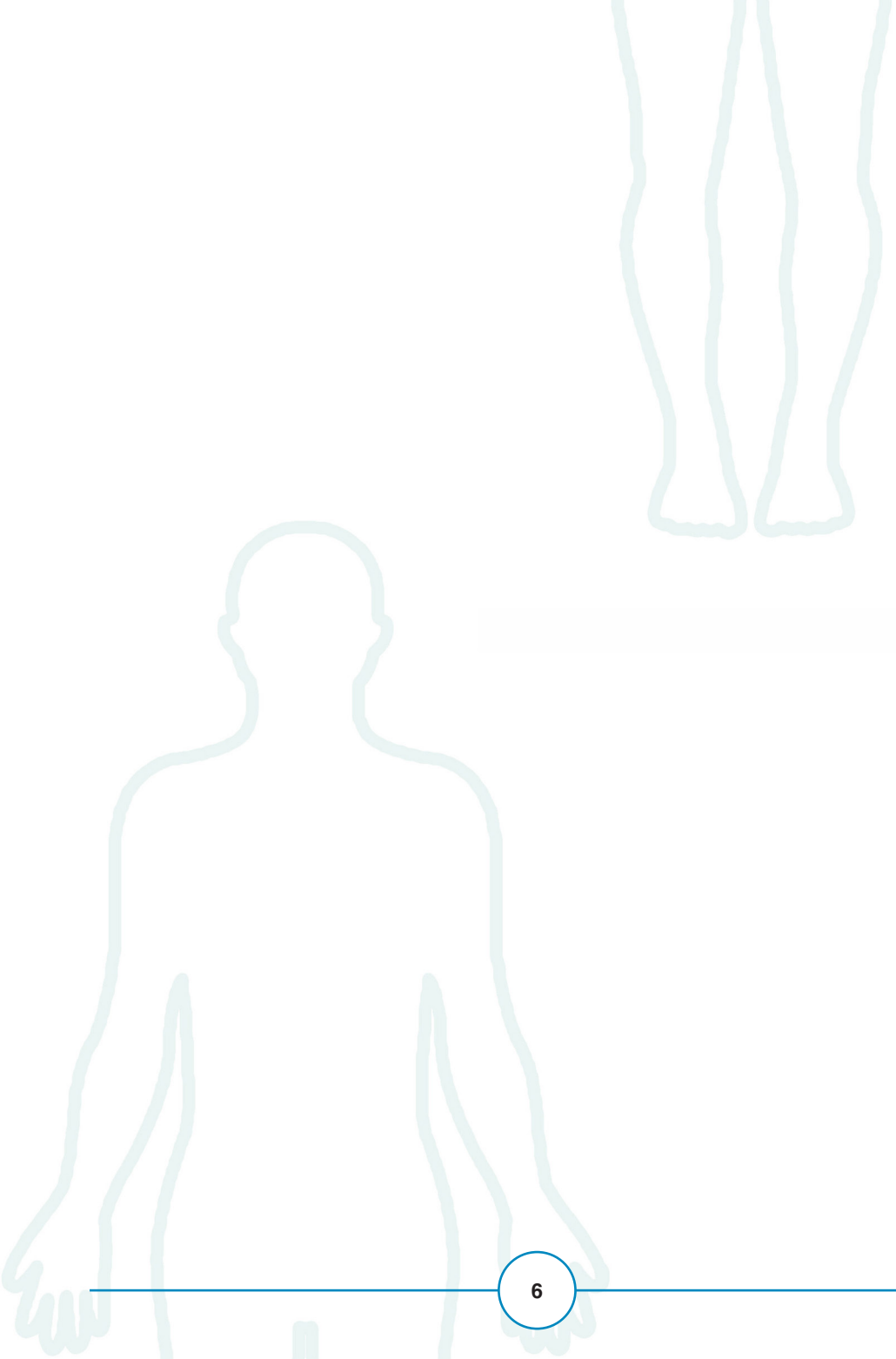
Dr Araújo-Vilar is a member of the Board of scientific advisors of AELIP, the President of the Governing Board of the European Consortium of Lipodystrophies and a member of the Governing Board of the European Lipodystrophy Registry. He is also the President and Founder of the Spanish Society for Lipodystrophies.

Dr Araújo-Vilar has published more than 40 scientific articles in this field.

**Sofía Sánchez-Iglesias** is a Doctor in Biochemistry from the University of Santiago de Compostela and a researcher in the UETeM-Molecular Pathology Group at the Center for Research in Molecular Medicine and Chronic Diseases (CiMUS) of the University of Santiago de Compostela.

**Cristina Guillín-Amarelle** is a Doctor of Medicine from the University of Santiago de Compostela, specialist doctor in Endocrinology and Nutrition and researcher in the UETeM-Molecular Pathology Group at the Center for Research in Molecular Medicine and Chronic Diseases (CiMUS) of the University of Santiago de Compostela.

**Antía Fernández-Pombo** is a specialist doctor in Endocrinology and Nutrition at the University Hospital Complex of Santiago de Compostela and a pre-doctoral researcher in the UETeM-Molecular Pathology Group at the Center for Research in Molecular Medicine and Chronic Diseases (CiMUS) of the University of Santiago de Compostela.

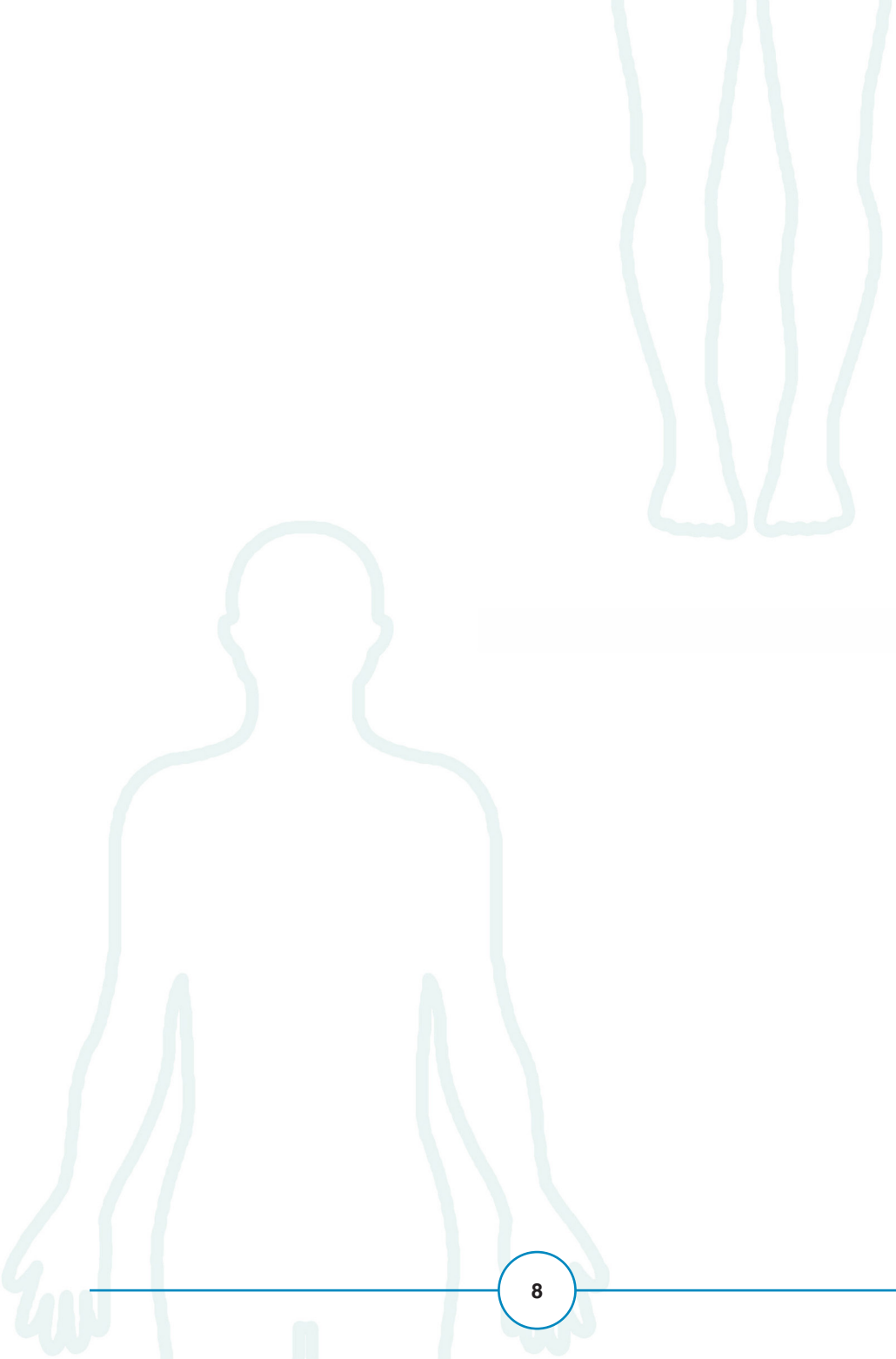




## INDEX

|   |    |
|---|----|
| Prologue .....  | 9  |
| 1. Introduction.....  | 17 |
| 2. Definition.....  | 18 |
| 3. Classification .....   | 18 |
| 4. Epidemiology .....   | 21 |
| 5. Diagnosis.....   | 21 |
| 6. Evaluation of the generalised lipodystrophies .....                          | 24 |
| 7. Congenital generalised lipodystrophy.....                                    | 24 |
| 8. Acquired generalised lipodystrophy.....                                      | 29 |
| 9. Evaluation of the partial lipodystrophies .....                              | 31 |
| 10. Familial partial lipodystrophy .....  | 31 |
| 11. Acquired partial lipodystrophies.....                                       | 38 |
| 11.1. Barraquer-Simons syndrome .....   | 38 |
| 11.2. Lipodystrophy associated to hematopoietic stem cell transplantation ..... | 39 |
| 12. Complex syndromes.....  | 41 |
| 13. Premature ageing syndromes .....  | 41 |
| 13.1. Progerias associated to generalised lipoatrophy.....                      | 42 |
| 13.2. Progerias associated to partial lipoatrophy .....                         | 50 |
| 14. Autoinflammatory syndromes .....  | 53 |
| 15. Localised lipodystrophies .....   | 54 |
| 16. Management and monitoring of patients with lipodystrophy.....               | 56 |
| 17. Treatment .....   | 61 |
| 18. References .....  | 72 |







It is an honor for me to be able to participate in this prologue with all that it means to have a guide of this significance. I write as the representative of patients and their family members who suffer from one of the infrequent lipodystrophies. I am the mother of Celia, a girl, my girl, who, during the 8 short years of her life, fought against the most severe and disabling rare pathology which lay, without our knowing, under the diagnosis of a lipodystrophy.

Since April 2012, as the President of AELIP, the International Association of Families and People Affected by Lipodystrophy, I have worked in collaboration with healthcare professionals, especially primary care doctors and paediatricians and, more specifically, the specialists responsible for dealing with the problems which attack the vital organs of those who suffer from one of the different types of infrequent lipodystrophies which can be found in this guide.

This guide will make it possible to promptly diagnose those affected and thereby reduce the anguish of uncertainty for whole families who, after long periods of waiting between medical tests, disoriented and without knowing what to do or who to consult, wait anxiously to receive what will possibly be the news which will mark their lives and, probably, those of their descendants.

I have always believed that there should be a protocol for doctors who have to give the diagnosis to families, aware of how difficult this part of such an intense and dedicated profession must be.

I will always remember the effect of that appointment on our lives, how, in a small grey room in the darkest corner of a hospital, I heard what was, and will probably always be, the worst news of my life.

Receiving the long-awaited and longed-for diagnosis in order to possess a weapon against the unknown is the news that will accompany each one of the days of the lives of those affected and of their families, who I have had the opportunity to meet in different regions and countries around the world.



As a direct, and affected, relative, I am also a carrier of the mutation which, along with my husband, I transmitted to our little princess, leaving her the worst of inheritances, a rare disease known as congenital lipodystrophy, Berardinelli-Seip syndrome.

I had never heard of this disease in my life, not in our desperate search which occupied every minute, nor even in all the information we found on the Internet.

Thus, I understand the dismay of the professionals who dealt with us in our medical practice and in the hospital in search of a solution (if possible, an immediate one) for our baby

Until that moment, going to the doctor with a baby meant coming home with a name and a treatment and a solution to the problem. That was what I knew as the procedure.

In those difficult times of conflicts with ourselves, as parents, we asked ourselves how we could explain to others something which had not yet been explained to us during the first two years of our baby's life. We did not even know the name of what our baby had, let alone a treatment. All we had was total uncertainty day after day, and always the same questions: How was the pregnancy? What happened in the first days of her life? How did you realise that something was wrong with her liver?

With each call we received from our immediate family, Celia's grandparents, her uncles and aunts, not having an answer gave us a sense of failure with our new family. What were we doing wrong? We needed an explanation for what was happening in order to look for the necessary means and to find our way out of that bitter episode. We hoped to receive an immediate cure (like any illness we had known until then) and to carry on enjoying life with our little one.

For this reason, I am writing to you and putting myself in your shoes, without tools or procedures to follow, questioning the humanity of the professional.

Therefore, it is a comfort to be able to have at our disposal this first practical guide for the diagnosis of lipodystrophies.

What follows in this guide has been learnt through suffering transformed into a professional tool for the relief of those affected. The alternative is a lack of knowledge leading us into the unknown, full of insecurity and with a negative outlook for any family plans.

For all the FAMILIES fighting to defend themselves against the adversities encountered living with an infrequent lipodystrophy anywhere in the world, for



those waiting to receive a diagnosis, this guide is of the greatest importance and necessity for all of them and for those to come.

What would be of the hopes of the human mind without the dedication to RESEARCH, one of the most invisible professions, only for the brave, who face a lack of means and investment.

These brave people employ today's most valuable resource, time. Time which they invest taking away from their family time and their free time, in the quest to meet a challenge, which sometimes, only sometimes, can be achieved.

There is only achievement and value for a few who dedicate their lives to research, who will remain forever in the history of humanity.

After all the suffering, there is a light at the end of the tunnel, an opportunity to look to the future, a hope without hope in my case and for so many others.

In our search, we encountered a professional who was already carrying out research in the field of lipodystrophies, my dear friend Dr David Araújo Vilar, a Galician par excellence, endocrinologist and professor of the University of Santiago de Compostela and a tireless defender of disciplined and rigorous teamwork.

I am eternally grateful to Dr Araújo and to those who give the best of themselves, investing their knowledge and efforts in collaborative teamwork in order to achieve goals such as these guidelines for the diagnosis of infrequent lipodystrophies.

My most sincere thanks to each and every one of the people who took part.

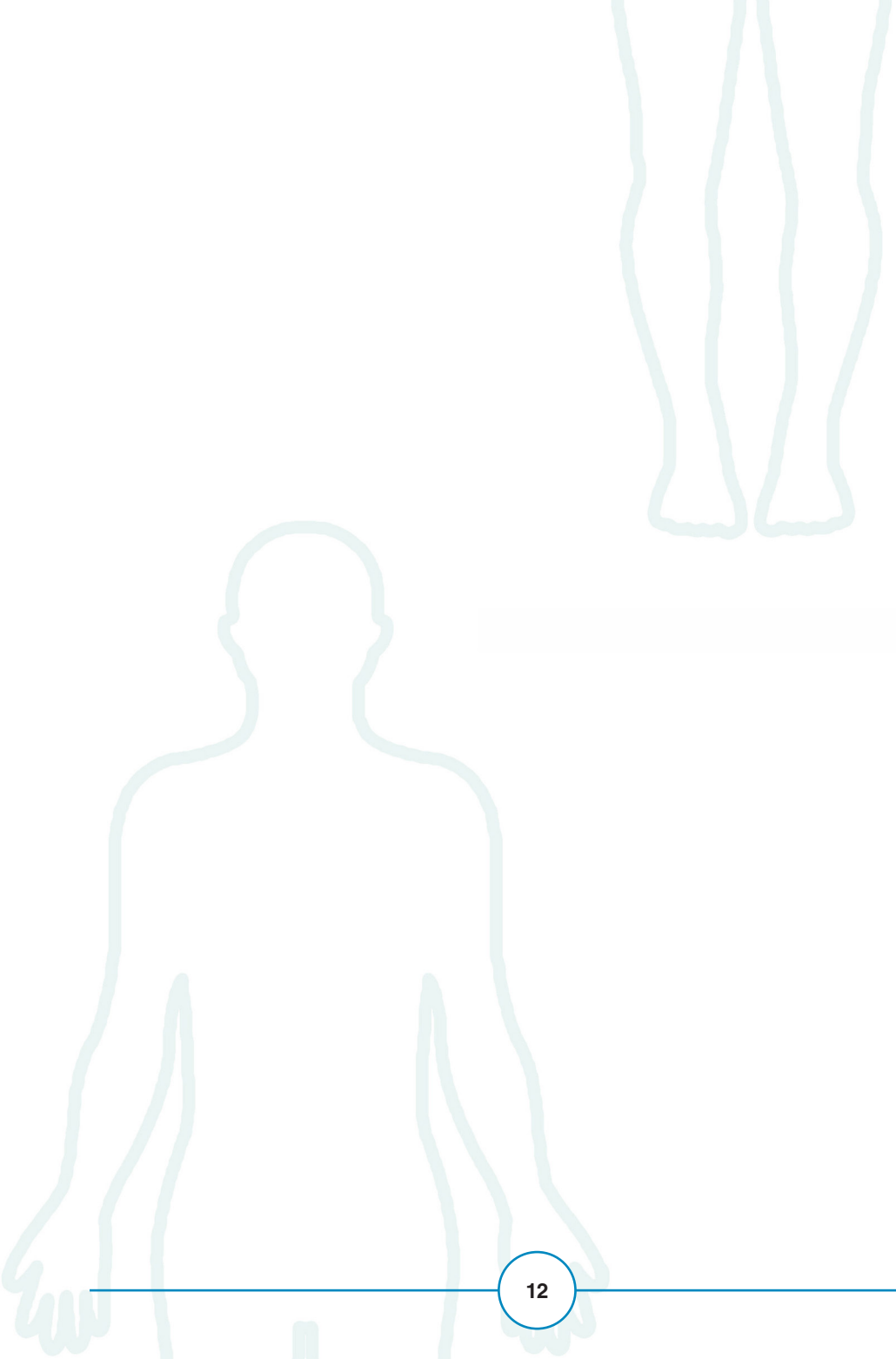
I particularly congratulate you, our mentor in research and world-renowned expert, David Araújo Vilar, for this great and long-awaited work.

My desire is that all who read these guidelines do so responsibly and to the benefit of all those involved, and I ask them to share them with their colleagues.

From the legacy which Celia left several of the proponents of these guidelines, I address with emotion all those who are willing to promote this guide.

Yours, Celia's mum

Naca Eulalia Pérez de Tudela Cánovas  
President of AELIP





Dear Friends,

It is a pleasure for me personally and for all the FEDER (Spanish Federation of Rare Disease) family to congratulate all the professionals involved in these practical guidelines for the diagnosis and treatment of infrequent lipodystrophies.

As you know, the common characteristics of rare diseases make them difficult to diagnose and, consequently, to treat effectively. Without going any further, practically half of the people who live with one of these pathologies in Spain have suffered delays in diagnosis, of which almost 20% have had to wait more than a decade.

The consequences which arise between the appearance of the first symptoms until a name is obtained for the disease are serious, both for the individual and for their family and social context. Therefore, the delay in obtaining a diagnosis deprives the patient of the necessary therapeutic intervention for the management of the disease. This brings, as a consequence, the worsening of the symptoms and physical, and sometimes intellectual and psychological effects, which could have been avoided with an early diagnosis.

A further problem in the case of genetic diseases like some of the lipodystrophies is that the lack of a diagnosis leads to tensions in the family, having to deal with an uncertainty which is not exempt from risk, as new cases may arise in children with the pathology.

To all of this can be added the fact that there is no treatment for 47% of us, or, if there is, it is not sufficient, a situation which is greatly affected by the moment at which the diagnosis is obtained. Indeed, the usefulness of an early diagnosis lies in being able to guarantee a management of the disease which ensures its appropriate prognosis.



Throughout this process, families are obliged to go on a pilgrimage around the health system in search of answers, thereby generating an impact on the family economy. This situation is exacerbated by the impossibility of gaining access to welfare benefits, the right to which depends on the existence of a diagnosis. The resulting physical, intellectual and psychological effects are, sometimes, irreversible both for the patient and for the family as a whole.

We are aware of the current situation and the difficulties caused by the delay in diagnosis, but what are the causes? One of the main causes is a lack of knowledge.

The difficulties in accessing information and the lack of coordination between departments and professionals in primary healthcare and hospitals have a great influence on the possibilities of putting a name to a disease.

Therefore, it is essential to put into effect guidelines such as these for training and information specific to infrequent diseases like lipodystrophies and to create systems of shared information to collect diagnostic activity and to bring together the experience of professionals, patients and even administrations in a clear example of networking.

AELIP, the International Association of Families and People Affected by Lipodystrophy, has managed to serve as a reference point for families and to promote training initiatives such as the International Lipodystrophy Symposium which involves all actors in this field. Furthermore, it supports different lines of research applied to the diagnosis and treatment of these pathologies.

Since its foundation in 2012, AELIP has worked with experienced centres such as the Endocrinology and Nutrition Department of the University Hospital Complex of Santiago de Compostela, where a Lipodystrophy Unit has been set up, led by Dr David Araújo-Vilar, who is also the force behind these guidelines.

Together with Dr Sofía Sánchez-Iglesias, Dr Cristina Guillín-Amarelle, and Dr Antía Fernández-Pombo, he has created this essential work for families, but, above all, for healthcare professionals who, like them, may be confronted with a lipodystrophy.

I would like to congratulate and thank each one of them not only for their effort and work on these guidelines but also for their daily dedication. In the area of rare diseases, families need people like them, for their specialisation, for prioritising the patients and for their commitment to increasing awareness of infrequent diseases.

In short, these Practical Guidelines for the Diagnosis and Treatment of Infrequent Lipodystrophies is a transversal work explaining the origin, management, and necessities of this group of pathologies.



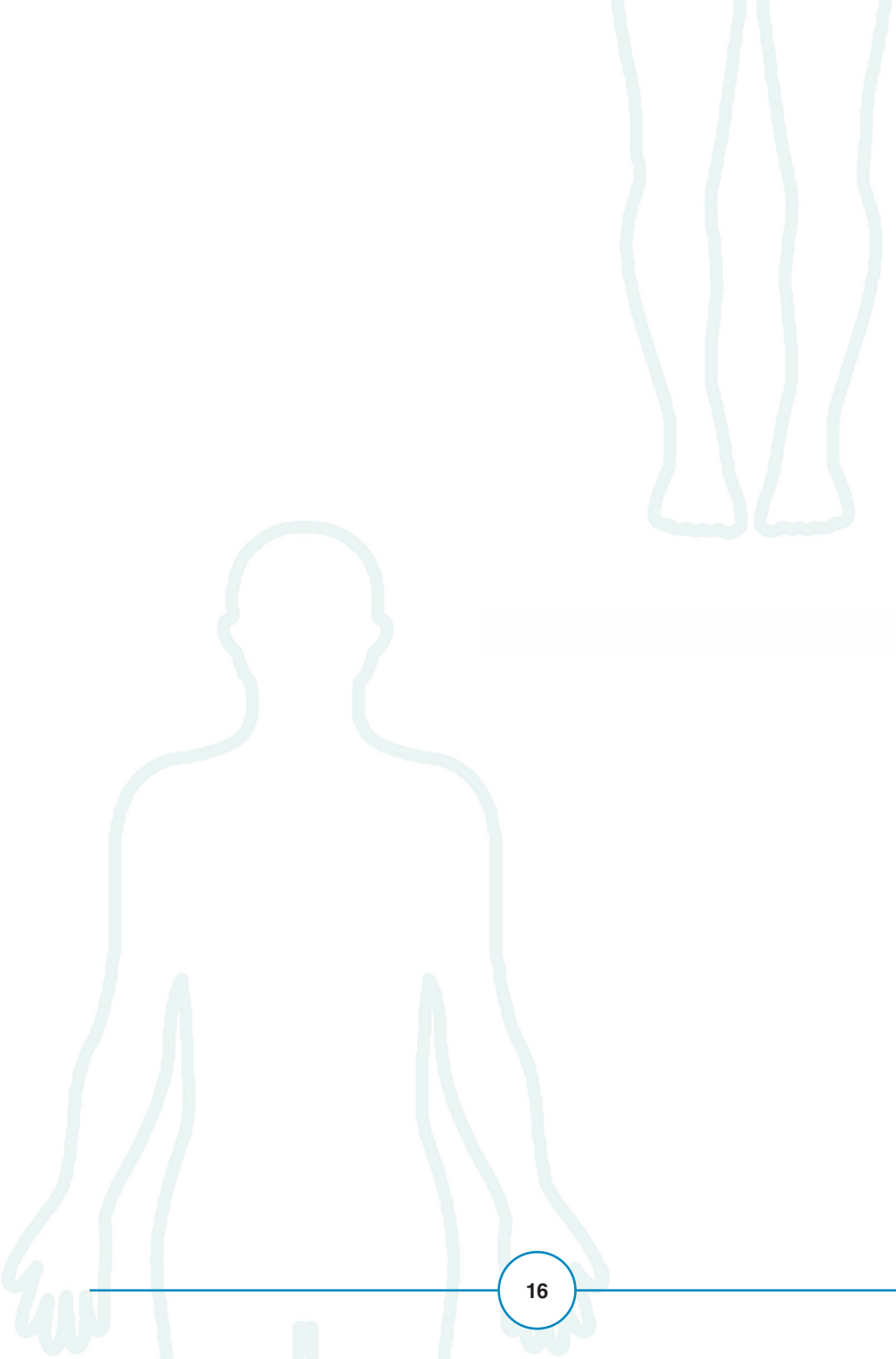
On behalf of the three million people living with an infrequent disease in Spain, those waiting to receive a diagnosis and all the associations of reference and the collective as a whole, thank you!

It is when we join forces and work in coordination, when we bring together our experience and knowledge that we can achieve the true transformation that our community needs and promotes.

Thank you for making it possible.

Juan Carrión  
President of FEDER and its Foundation







## 1. INTRODUCTION

Etymologically, the word **lipodystrophy** comes from the Greek Lipo (λιπο-), which means **fat**, -dys (δυσ-), which means **bad** and -troph (τροφος), meaning **nutrition**; in other words, it is literally “bad nutrition of fat”. More appropriately, it could be said that lipodystrophy refers to those disorders in which adipose tissue, fat, is defective or altered in its structure and/or function.

The lipodystrophies are nosological entities which are, with the exception of that associated to the human immunodeficiency virus (HIV) infection, extremely infrequent, but which, in general, have serious consequences for those who suffer from them. These diseases may significantly reduce their life expectancy, are often associated with complications in different organs and systems and always lead to alterations in the individual’s physical appearance. Indeed, these disorders can be associated to a severe form of metabolic syndrome caused by the abnormal depot of fat which cannot be stored in the appropriate subcutaneous tissue [Diker-Cohen 2015]. The loss of adipose tissue often results in a reduction in leptin levels [Haque 2002], which interferes with hunger-fullness signals and often leads to hyperphagia [Garg 2004]. The excess of calories is stored as fat in the liver and muscular tissue, leading to insulin resistance, hypertriglyceridemia, and fatty liver disease.

The extreme rarity of these disorders means that they are not well-known, not only by the general public but also by doctors, including the specialists such as endocrinologists and paediatricians, who, for obvious reasons, should be more aware of them. All of this means that their diagnosis is often difficult and frequently incorrect and late, and that curative care has not been developed. This last aspect is closely linked to the fact that there are few research groups dedicated to these diseases around the world, which is a common factor in the case of rare diseases.

All of this is added to the fact that the clinical characterisation of lipodystrophies is often deficient, that there is a great degree of phenotypical variability between the different subtypes of lipodystrophy and that the aetiology is diverse (and sometimes unknown) as are the pathogenetic mechanisms which lead to the alteration of adipose tissue.



Therefore, the aim of these Guidelines is to offer professionals a practical tool for a trustworthy diagnostic approach to the more than 40 subtypes of lipodystrophies described to date, based on the scientific knowledge currently available, while remaining aware that certain lipodystrophic conditions will continue to exist in a diagnostic limbo. Furthermore, we aim to provide a therapeutic approach to the complications associated with these disorders, bearing in mind that, to the present time, there is no cure for lipodystrophies. Lipodystrophy associated to HIV infection is out of the scope from these guidelines.

## 2. DEFINITION

In spite of the etymology of the word “lipodystrophy”, a consensus exists in the scientific community that lipodystrophies are a heterogeneous set of disorders characterised by a loss, or the disappearance, of adipose tissue once other causes associated to wasting or weight loss have been ruled out, such as cancer cachexia, badly-controlled diabetes, malnutrition, anorexia nervosa, thyrotoxicosis and chronic infections [Brown 2016, Araújo-Vilar 2018]. In some subtypes, the loss of adipose tissue in certain areas of the body is associated with an abnormal accumulation in others. As a general rule, with rare exceptions [Patni 2015], the loss of fat is not recovered.

## 3. CLASSIFICATION

Lipodystrophies may be classified according to the extension of the loss of fat into generalised, partial and localised; and, according to their aetiology, into congenital and acquired. Initially, four subtypes of infrequent lipodystrophies were established; congenital generalised lipodystrophy (CGL) or Berardinelli-Seip syndrome, generalised acquired lipodystrophy (GAL) or Lawrence syndrome, familial partial lipodystrophy and partial acquired lipodystrophy or Barraquer-Simons syndrome [Garg 2004, Brown 2016]. Over recent years, this classification has become more and more complex as new phenotypes have been discovered in which the loss of adipose tissue is just one more feature of these diseases [Araújo-Vilar 2018]. Each subtype, on the other hand, includes variants with particular clinical characteristics, different aetiologies and pathogenetic mechanisms. An updated classification of lipodystrophies is shown in Table 1.



**Table 1.** Classification of the Lipodystrophies

| <b>Congenital</b>  | <b>Type of inheritance</b> |
|--|----------------------------|
| <b>Generalised (Berardinelli-Seip syndrome)</b>                            |                            |
| Type 1 (AGPAT2)  | AR                         |
| Type 2 (BSCL2)   | AR                         |
| Type 3 (CAV1)  | AR                         |
| Type 4 (PTRF)  | AR                         |
| Associated to PPARG  | AR                         |
| <b>Familial Partial</b>  |                            |
| Type 1 or Köbberling syndrome  | AD/Polygenic               |
| Type 2 or Dunnigan disease (LMNA)  | AD                         |
| Type 3 (PPARG)   | AD                         |
| Type 4 (PLIN1)   | AD                         |
| Type 5 (CIDEA)   | AR                         |
| Type 6 (LIPE)  | AR                         |
| Associated to AKT2   | AD                         |
| Associated to PCYT1A   | AR                         |
| Associated to ADRA2A   | AD                         |
| Associated to MFN2   | AD                         |
| <b>Complex syndromes</b>   |                            |
| Premature ageing syndromes   |                            |
| Associated to generalised lipoatrophy                                      |                            |
| Hutchison-Gilford syndrome (LMNA)  | AD (de novo)               |
| Mandibuloacral dysplasia type B (ZMPSTE24)                                 | AR                         |
| Néstor-Guillermo syndrome (BANF1)  | AR                         |
| Atypical progeroid syndrome* (LMNA)  | AD (de novo)               |
| MDPL (POLD1)   | AD (de novo)               |
| Marfan syndrome with neonatal progeroid syndrome-like lipodystrophy (FBN1) | AD (de novo)               |
| Cockayne syndrome (ERCC6, ERCC8)   | AR                         |
| Keppen-Lubinsky syndrome (KCNJ6)   | AD (de novo)               |
| Ruijs-Aalfs syndrome (SPRTN)   | AR                         |

\*Atypical progeroid syndrome can also be associated to partial lipodystrophy or may not present with lipodystrophy.



|  |    |
|--|----|
| Associated to partial lipodystrophy  |    |
| Mandibuloacral dysplasia type A (LMNA)                                       | AR |
| Werner syndrome (RECQL2/WRN)   | AR |
| SHORT (PIK3R1)   | AD |
| Bloom syndrome (BLM)   | AR |
| Fontaine Progeroid Syndrome (SLC25A24)                                       | AD |
| Neonatal Progeroid syndrome (Wiedemann-Rautenstrauch syndrome)(POLR3A, CAV1) | AR |
| Autoinflammatory syndromes   |    |
| Nakajo-Nishimura syndromes (PSMB8)   | AR |
| JMP (PSMB8)  | AR |
| CANDLE syndrome (PSMB8)  | AR |

## Acquired

---

### Generalised

- Acquired generalised lipodystrophy or Lawrence syndrome
- Autoimmune variant
- Variant associated to panniculitis
- Idiopathic variant

### Partial

- Associated to HIV infection
- Partial acquired lipodystrophy, cephalocaudal or Barraquer-Simons
- Syndrome associated to transplantation of hematopoietic stem cells

### Localised

- Associated to drugs (insulin, corticoids, pegvisomant)
- Semicircular lipodystrophy
- Lipodystrophy centrifugalis abdominalis infantilis
- Associated to panniculitis
- Idiopathic

---

*In brackets the gene responsible for each subtype of congenital lipodystrophy.*

AD: Autosomal dominant; AR: Autosomal recessive; MDPL: mandibular hypoplasia, deafness, progeroid features, and lipodystrophy syndrome; SHORT: acronym of S = stature; H = hyperextensibility of joints or hernia (inguinal) or both; O = ocular depression; R = Rieger anomaly; T = teething delay; JMP: joint contractures, muscle atrophy, microcytic anaemia, and panniculitis-induced lipodystrophy; CANDLE, chronic neutrophilic dermatosis with lipodystrophy and elevated temperature.



## 4. EPIDEMIOLOGY

As these diseases are extremely infrequent, it is difficult to establish their real prevalence. However, it has been estimated, based on searches of large electronic medical databases that, excluding the lipodystrophy related with HIV infection, the worldwide prevalence of lipodystrophy is 3.07 cases per million inhabitants (0.23 cases per million for generalised lipodystrophy [GL] and 2.84 cases per million for partial lipodystrophy [PL]). Through bibliographic research, it had been estimated that the prevalence of GL and PL was 0.96 and 1.67 cases per million inhabitants, respectively [Chiquette 2017].

## 5. DIAGNOSIS

The diagnosis of a lipodystrophy is based on the patient's medical history, physical examination and the evaluation of body composition, with certain laboratory results proving useful in some cases. Despite the fact that no diagnostic criteria have been established for lipodystrophy based on the measurement of skin folds (Table 2) or on imaging techniques such as dual-energy X-ray absorptiometry (DXA) (Table 3) and magnetic nuclear resonance, these tests may prove to be of assistance in the diagnosis [Garg 1992, Agarwal 2003, Misra 2003, Misra 2004, Guillín-Amarelle 2016]. Although the serum levels of leptin in patients with lipodystrophy tend to be low (either in absolute levels or in relation to the body mass index), it is not possible to use a defined threshold of leptin serum concentration to discard the diagnosis of lipodystrophy [Brown 2016].

**Table 2.** Skin folds [Brown 2016]. Thickness values of the skin fold below the 10<sup>th</sup> percentile may increase the suspicion of lipodystrophy, although they are not diagnostic.

| Location         | Adult males (1) | Adult females (2) | Boys (3) | Girls (4) |
|------------------|-----------------|-------------------|----------|-----------|
| Thorax (mm)      | 5               | 6.5               | 3        | 4         |
| Axilla (mm)      | 6               | 6.5               | 3        | 4         |
| Subscapular (mm) | 8               | 7.5               | 4        | 5         |
| Suprailiac (mm)  | 6               | 6                 | 4        | 7         |
| Abdomen (mm)     | 9               | 12.2              | 5        | 6.5       |
| Triceps (mm)     | 6               | 11                | 6        | 7.5       |
| Thigh (mm)       | 8               | 19.5              | 9        | 13        |
| Calf (mm)        | ND              | ND                | 6        | 8         |



The values for adult males are for men from 18 to 61 years of age (1); the values for adult females are for women from 18 to 55 years of age; the values for boys are for prepubescent boys from 4 to 10 years of age and the values for girls are for prepubescent girls from 4 to 10 years of age (3 and 4).

**Table 3.** Percentage of body fat in slim healthy adults quantified via DXA.

| Location    | Men | Women |
|-------------|-----|-------|
| Total       | 12  | 23    |
| Trunk       | 10  | 18    |
| Upper limbs | 12  | 23    |
| Lower limbs | 12  | 26    |

Values corresponding to the 1<sup>st</sup> decile obtained from 17 healthy males of between 20 and 40 years of age, with BMI between 18.7 and 24.9 kg/m<sup>2</sup> and from 23 healthy females of between 23 and 42 years of age, with BMI between 18 and 24.6 kg/m<sup>2</sup>.

As will be seen below, the generalised lipodystrophies normally present an easily recognisable phenotype, whereas the presentation of the partial lipodystrophies may be more subtle, being recognised, in part, by a characteristic pattern of fat loss [Garg 2004, Misra 2004, Vantyghem 2012]. Patients with lipodystrophy may present with the illness in childhood or in adulthood and the onset can be sudden or insidious. With few exceptions [Patni 2015], one of the main characteristics of lipodystrophies is that the fat loss is never recovered.

Lipodystrophy must be suspected when a patient presents a congenital deficiency of subcutaneous adipose tissue (SAT), a progressive loss of SAT associated with autoimmune diseases, a loss of SAT in the limbs associated with the accumulation of fat in other areas of the body or the deficiency of SAT associated with other somatic anomalies [Garg 2011]. Additional physical characteristics may include growth delay (in children), prominent muscles and veins, acanthosis nigricans, eruptive xanthomatosis and Cushingoid and acromegaloid appearance [Brown 2016]. The diagnosis can be reinforced if the patient also presents diabetes mellitus associated to severe insulin resistance, severe hypertriglyceridemia, non-alcoholic fatty liver disease or polycystic ovary syndrome (PCOS) [Garg 2011].

The **differential diagnosis** in the case of the generalised lipodystrophies includes a range of diverse conditions of severe weight loss [Garg 2011, Araújo-Vilar 2018, Guillín-Amarelle 2018], such as the following: anorexia nervosa, starvation, malnutrition, uncontrolled diabetes, thyrotoxicosis, adrenal



insufficiency, cancer cachexia and severe chronic infection. In the case of certain subtypes, such as Berardinelli-Seip syndrome, and, to a lesser extent, Lawrence syndrome, the associated hyperinsulinemia may bring about the appearance of acromegaloid features beginning in puberty/adolescence, which may be confused with acromegaly.

The partial lipodystrophies, particularly familial partial lipodystrophy, may be confused with Cushing syndrome due to the accumulation of fat in the face and neck. However, Cushing syndrome does not present with lipoatrophy in the limbs, but rather with an abnormal distribution of body fat [Rockall 2003]. Neither does it present with muscular hypertrophy, well-defined musculature or flebomegaly. In any case, with both the suspicion of chronic hypercortisolism and of acromegaly, the corresponding biochemical exams enable them to be discarded with certainty.

Severe acanthosis nigricans is usually a cutaneous stigma present in many lipodystrophies, particularly in Berardinelli-Seip syndrome and Lawrence syndrome. Other conditions which present with severe acanthosis nigricans are the syndromes of severe insulin resistance, particularly Donohue syndrome (or leprechaunism) and Rabson-Mendenhall syndrome, both of which are caused by biallelic variants in the gene which encodes the insulin receptor (INSR). Although Donohue syndrome can be associated to a certain degree of lipodystrophy in the limbs, it presents a particular phenotype which is difficult to confuse with Berardinelli-Seip syndrome. These children have craniofacial anomalies which include elfin face, large low-set ears, growth delay, reduced muscle mass, hypertrichosis, pachydermia, virilisation and insulin resistance with paradoxical hypoglycaemia. Death often occurs in early childhood. On the other hand, children with Rabson-Mendenhall syndrome have much longer survival rates (15-20 years) and have rugged faces with prognathism, dental crowding, short stature, thin but not lipoatrophic bodies, extremely severe acanthosis nigricans, phallic enlargement or clitoromegaly, paradoxical hypoglycaemia, hyperinsulinemia and diabetic ketoacidosis [West 1975].





## 6. EVALUATION OF THE GENERALISED LIPODYSTROPHIES

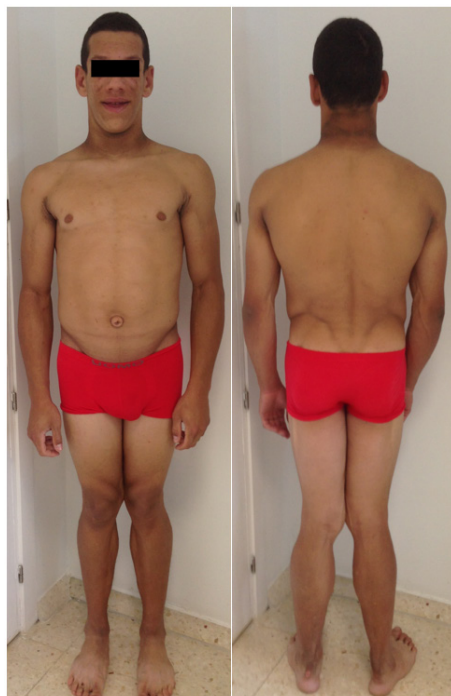The generalised lipodystrophies include congenital generalised lipodystrophy (CGL or Berardinelli-Seip syndrome), acquired generalised lipodystrophy (AGL or Lawrence syndrome) and certain premature ageing disorders (progeroid syndromes). One key, but not pathognomonic, characteristic for establishing the presence of CGL is the age at which weight loss begins, usually at birth or during the first year of life. However, in some subtypes of CGL (Lawrence syndrome and some progeroid syndromes), the lipodystrophy appears during childhood.

## 7. CONGENITAL GENERALISED LIPODYSTROPHY

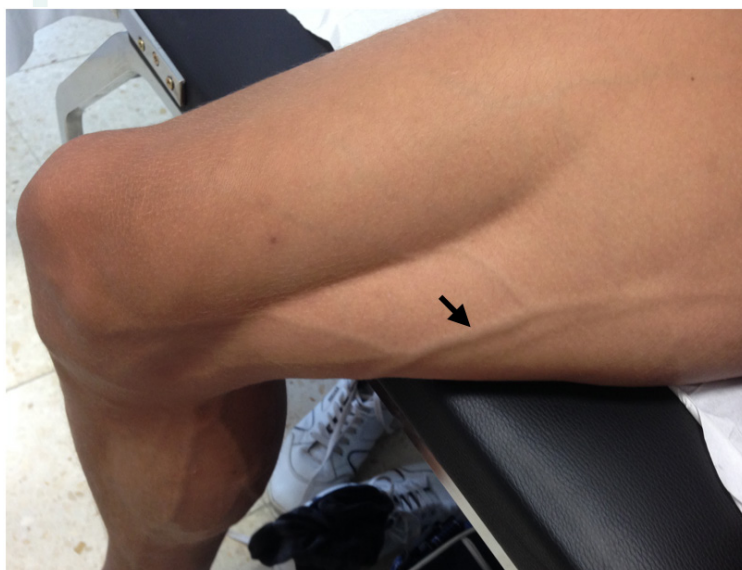### (Berardinelli-Seip syndrome)

Berardinelli-Seip syndrome is an autosomal disorder associated with an almost total absence of adipose tissue (Fig. 1) [Brown 2016, Agarwal 2003]. The loss of adipose tissue becomes evident at birth or during the first year of life in subtypes 1 [MIM: #608594] and 2 (MIM: #269700), whereas usually it appears during childhood in subtypes 3 and 4 [Brown 2016]. Patients have a well-defined musculature, phlebomegaly in both upper and lower limbs (Fig. 2), and acanthosis nigricans with acrochordons (Fig. 3), which commonly extend beyond the axillae and the neck and affect the groin, the elbow bend and the abdomen [Brown 2016, Hussain 2016]. Patients may exhibit acromegaloid features (Fig. 4), which normally become more evident from adolescence. Abdominal distension (Fig. 5), due to an enlarged liver, is generally observed from early childhood: Hernias or umbilical protrusion are common (Fig. 6) [Garg 2011, Brown 2016]. In some cases, hypertrichosis is characteristic (Fig. 7) [Garg 2011]. A voracious appetite is common in early childhood [Garg 2004]. Generally, these patients present accelerated growth during the early years of life, although their final height corresponds to the height of their parents.

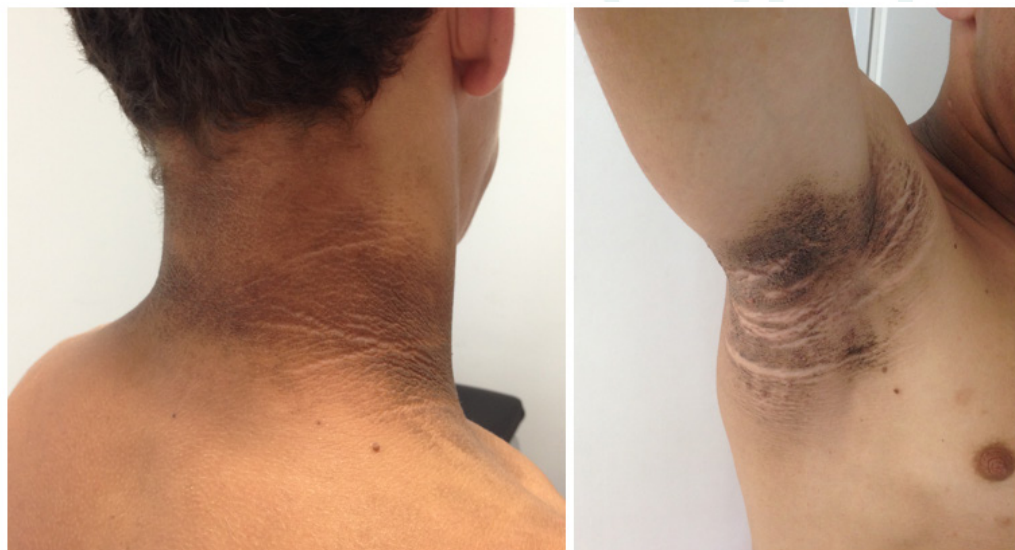From the first months with the disease, patients with CGL may present with hypertriglyceridemia, which, if severe, can lead to acute pancreatitis [Garg 2011]. Plasma levels of insulin are high and nonketotic diabetes, which generally appears during the second decade of life, is often extremely difficult to control, even with high doses of insulin [Garg 2011]. Without treatment, the prognosis for patients with CGL is poor (death before the age of 50) due to liver cirrhosis, the cardiovascular complications of diabetes, pancreatitis, sepsis or terminal kidney disease [Garg 2011].



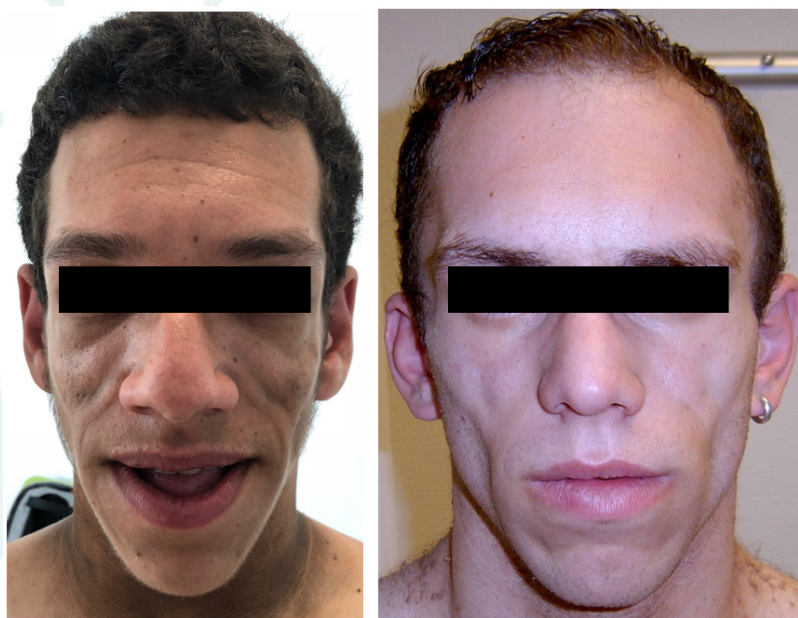**Figure 1.** Berardinelli-Seip syndrome type 2



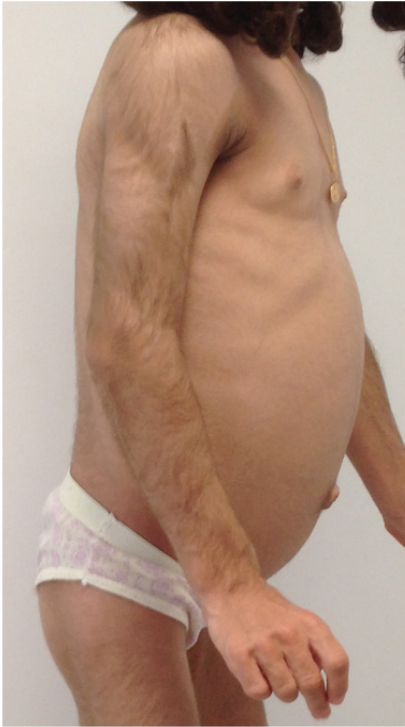**Figure 2.** Phlebomegaly in a patient with Berardinelli-Seip syndrome type 2.



**Figure 3.** Acanthosis nigricans and acrochordons in a patient with Berardinelli-Seip syndrome type 2.



**Figure 4.** Acromegaly features in two patients with Berardinelli-Seip syndrome type 2.

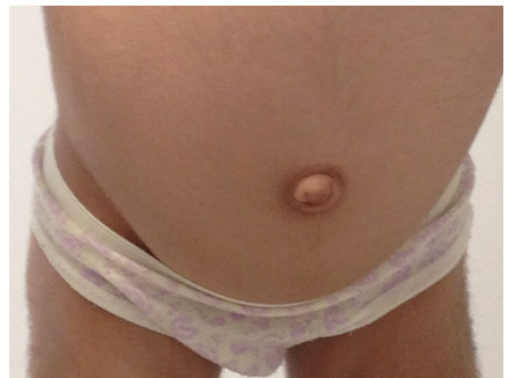
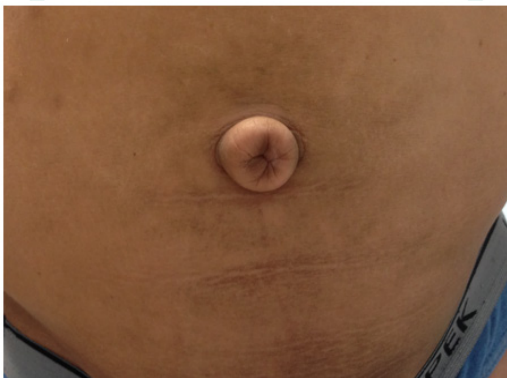
**Figure 5.** Abdominal distension due to hepatomegaly and hypertrichosis in a patient with Berardinelli-Seip syndrome type 2.

The average leptin level in CGL patients is 1 ng/ml and is low independently of sex and age [Lima 2016].

In some cases, the family history and, almost always, the phenotypical features of the patients will help in the diagnosis of Berardinelli-Seip syndrome. The presence of consanguinity must be taken into account, as the existence of blood connections in the parents of the proband would be suggestive of Berardinelli-Seip syndrome, and the presence of an affected sibling would almost confirm the diagnosis, as long as certain phenotypical features are associated.

Certain clinical characteristics may be associated with the gene responsible for each subtype of Berardinelli-Seip syndrome [Brown 2016, Garg 2011] (Table 1), although genetic tests are required in order to confirm the subtype of CGL [Brown 2016]. Subtypes 1 (associated to the *AGPAT2* gene) and 2 (associated to the *BSCL2* gene) of CGL are the most common, with subtype 2 having the most severe metabolic complications and an

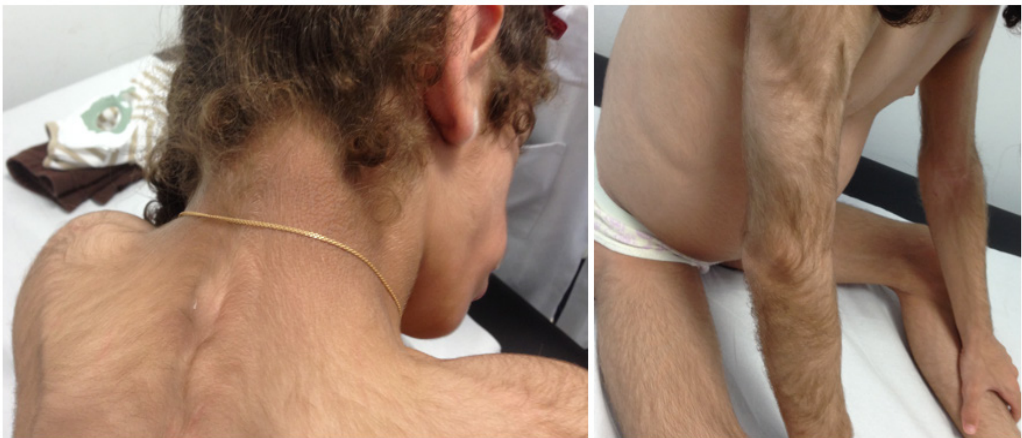

**Figure 6.** Umbilical protrusion in two patients with Berardinelli-Seip syndrome type 2.



association with a slight-medium degree of intellectual disability [Garg 2011, Agarwal 2003]. In particular, some variants in *BSCL2* are associated with a lethal encephalopathy in early childhood [Guillén-Navarro 2013]. Patients with variants in *BSCL2* have lower levels of leptin and an earlier onset of diabetes than in the other subtypes [Agarwal 2003]. Hypertrophic cardiomyopathy has been described, as has accelerated growth in subtypes 1 and 2 and, in women, clitoromegaly and precocious puberty [Garg 2011, Van Maldergem 2002]. On the other hand, mechanical fat (for example on the palms and soles of the feet) is sometimes reduced in subtype 2, while it is conserved in other subtypes [Garg 2011, Simha 2003].

Additional clinical characteristics, such as contraction response to muscle percussion, muscular weakness, atlantoaxial instability, sometimes malign cardiac arrhythmias, osteopenia, distal metaphyseal deformation with joint stiffness, hypertrophic pyloric stenosis and oesophageal dysmotility can be very suggestive of Berardinelli-Seip syndrome type 4 (MIM: #613327) [Hayashi 2009, Rajab 2010], associated to variants in the *PTRF* gene. Recently, Sorkina et al. [2020] have reported a case of type 4 CGL in whom lipodystrophy appeared since the first months of life, with particular associated co-morbidities as vitamin D deficiency, hypocalcemia, bilateral cataracts and hyperuricemia. Certain biallelic variants in the *PPARG* gene have been associated to congenital generalised lipodystrophy, which presents with refractory diabetes, hypertriglyceridemia, pancreatitis, irregular menstruations and kidney failure [Dyment 2014].



**Figure 7.** Hypertrichosis in a patient with Berardinelli-Seip syndrome type 2.



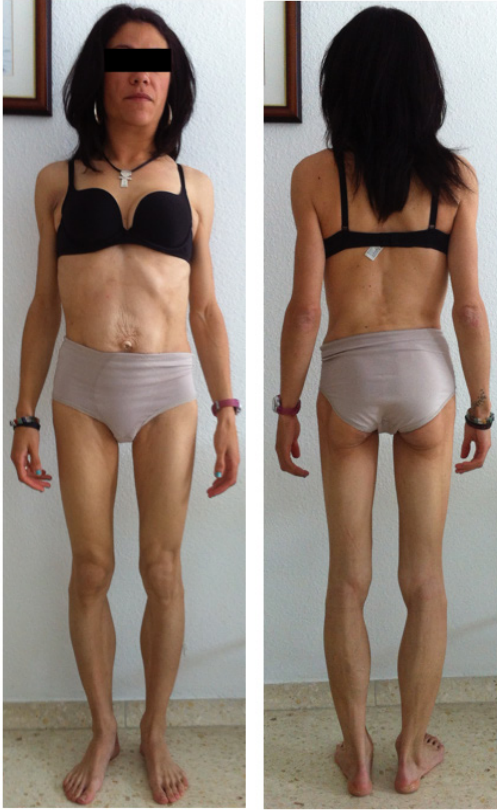Celia's encephalopathy or progressive encephalopathy with/without lipodystrophy (PELD, MIM: #615924) is an extremely rare subtype of Berardinelli-Seip syndrome type 2 due to the variant c.985C>T in the BSCL2 gene [Guillén-Narvarro 2013]. This disease is characterised by an extremely severe epileptic encephalopathy which appears at 2 years of age as a psychomotor retardation and which, from 3-4 years of age, manifests with a neurological regression particularly affecting language and, later, cognitive and motricity capacities. At around 4-5 years of age, myoclonic epilepsy normally appears, which is extremely difficult to control pharmacologically. Death occurs between 7 and 9 years of age as a consequence of the neurological disorder. In homozygous patients, lipoatrophy is not so apparent as in compound heterozygous patients. However, the metabolic and hepatic alterations of Berardinelli-Seip syndrome (hypertriglyceridemia, low HDL cholesterol, insulin resistance, fatty liver disease) are present from the first months after birth. Other variants in BSCL2 have been reported related with PELD [Sánchez-Iglesias 2019, Pedicelli 2020].

## 8. ACQUIRED GENERALISED LIPODYSTROPHY

### (Lawrence syndrome)

Compared with CGL, AGL has a much later onset (childhood or adolescence) and is more common in women than in men (proportion 3:1) (Fig. 8) [Misra 2003, Araújo-Vilar 2018]. The loss of adipose tissue during childhood or adolescence, affecting almost the entire body, preceded or followed by autoimmune manifestations in other organs, is extremely suggestive of AGL [Brown 2016]. Initially, subcutaneous fat loss may occur in limited areas of the body but tends to generalise with the progression of the disease over the course of weeks, months or years. On occasions, the loss of facial fat is not initially present, although it generally occurs with time. In some cases, AGL is a phenocopy of Berardinelli-Seip syndrome.

Insulin-resistant diabetes, severe hypertriglyceridemia, fatty liver disease and the stigmas of insulin resistance are common comorbidities of Lawrence syndrome. Hyperinsulinemia and low leptin levels in plasma are typically present. The loss of fat in the palms and soles of the feet has been reported in approximately a third and half of patients, respectively [Misra 2003]. In some patients, renal tubular lipidosis and focal glomerulosclerosis have been reported [Giralt 2017]. As it is an acquired disease, there is no family history of lipodystrophy in these cases, although the presence of other autoimmune diseases in relatives may help in the



**Figure 8.** Patient with Lawrence syndrome

diagnosis. The activation of the classical complement pathway and low levels of complement C4 have been associated with low levels of leptin and adiponectin and with the destruction of adipocytes and lipodystrophy in these patients [Savage 2009].

Three subtypes of AGL (associated to panniculitis, autoimmune and idiopathic) have been proposed [Misra 2003]. The onset of the lipodystrophy has been associated with the appearance of panniculitis in ~ 25% of cases and with the presence of other autoimmune diseases in another 25%, whereas no specific causes have been able to be identified in the majority of cases (idiopathic subtype). Patients who develop AGL in association with an autoimmune disease tend to be older than those with other subtypes [Misra 2003]. In particular, juvenile autoimmune dermatomyositis has been associated with AGL [Huemer 2001]. The disco-

covery of the first autoantibody (anti-perilipin 1) related with the aetiology of certain cases of Lawrence syndrome has recently been published [Corvillo 2018]. In accordance with an analysis of a series of cases, the disease associated to panniculitis can progress more slowly than autoimmune or idiopathic AGL, with a lower prevalence of diabetes and hypertriglyceridemia [Misra 2003].

Recently, it has been reported some cases of acquired generalised lipodystrophy after treatment with anti-programmed cell death-1 (anti-PD-1) antibodies (nivolumab, pembrolizumab) for metastatic melanoma or other types of cancer. These patients presented with a rapidly progressive generalized loss of subcutaneous adipose tissue, diabetes associated with severe insulin resistance and undetectable plasma leptin [Falcao 2019, Jehl 2019, Gnanendran 2020].



## 9. EVALUATION OF THE PARTIAL LIPODYSTROPHIES

The distribution of fat loss, the age of onset, certain phenotypical features and family history are determining factors in the diagnosis of the subtypes of partial lipodystrophy, which include congenital and acquired disorders (Table 1).

## 10. FAMILIAL PARTIAL LIPODYSTROPHY

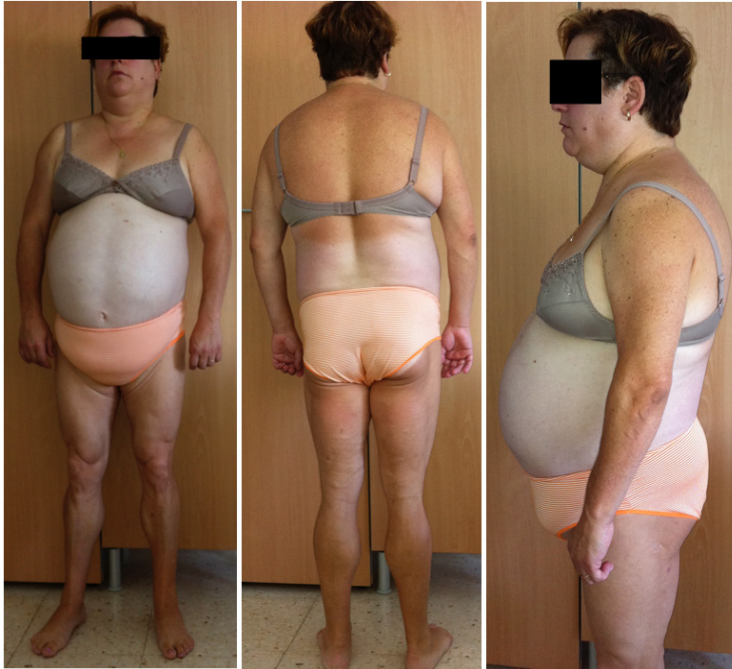Familial Partial Lipodystrophy (FPLD) includes a set of disorders which share a Cushingoid appearance and a variable association with an excess of body weight. A loss of subcutaneous fat in the limbs and the gluteal region, which usually appears during childhood or puberty in women and later in men, associated with the accumulation of fat in the face, neck and intra-abdominal region, is extremely suggestive of FPLD [Garg A 2011b].

Up to 10 subtypes of FPLD have been reported depending on the responsible gene (Table 1).

**FPLD type 1** (Köbberling syndrome, MIM: #608600) is a hereditary variety with an early onset (childhood/adolescence), although it may begin in early adulthood. To date, no specific genes responsible for this disorder have been identified, with the suggestion of a dominant or polygenic inheritance pattern [Köbberling 1986, Guillín-Amarelle 2016, Lotta 2017]. The diagnosis of FPLD type 1 is challenging as it can easily be confused with android obesity in women associated to metabolic syndrome. Patients with FPLD type 1 are generally obese, present with diabetes and hypertriglyceridemia, and have a significant accumulation of abdominal fat with more evident lipoatrophy in the buttocks, hips and lower limbs (Fig. 9) [Guillín-Amarelle 2016]. Although it is not always the case, acanthosis nigricans may be present. The disease can be part of a spectrum which includes essential central obesity and specific cut-off points have been proposed for the thickness and distribution of subcutaneous fat (KöB index), which may be useful when distinguishing between Köbberling syndrome and androgenic obesity in women [Guillín-Amarelle 2016]. Due to the characteristic distribution of fat in obese men (predominantly central) and the absence of a specific responsible gene, it is not possible to diagnose this disorder in men.

**FPLD type 2** or Dunnigan disease (MIM: #151660) [Guillín-Amarelle 2018] follows an autosomal dominant inheritance pattern. The classical phenotype of Dunnigan disease is associated to variants in exon 8 of the LMNA gene (Fig. 10), although many other variants in other exons have been reported. In its classical form, fat loss begins around puberty in women, affecting the limbs, trunk,





**Figure 9.** Patient with Köbberling syndrome

hips and buttocks. Strikingly, these patients have an accumulation of fat in the face, neck, axillae, interscapular region, the visceral abdominal area and the labia majora [Bidault 2011]. In men, this pattern of fat loss appears much later and is less evident [Araújo-Vilar 2003]. Indeed, affected men are generally diagnosed based on their female relatives.

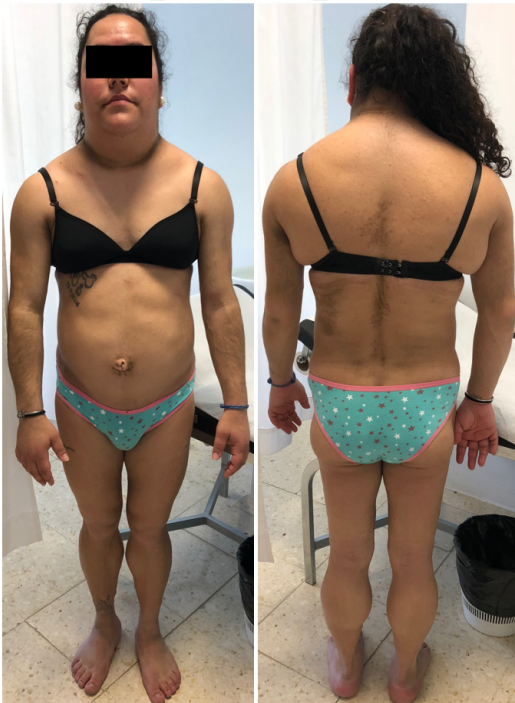Their musculature is well-defined, and muscular hypertrophy in the calves may even be present (Fig. 11). This well-defined and augmented musculature, along with the particular distribution of fat, confer an android appearance upon these women [Brown 2016, Ji 2013]. Phlebomegaly is common in the upper and lower limbs (Fig. 12) and their hands are normally broad and with short fingers.

These patients present metabolic, cardiovascular, hepatic and pancreatic comorbidities.

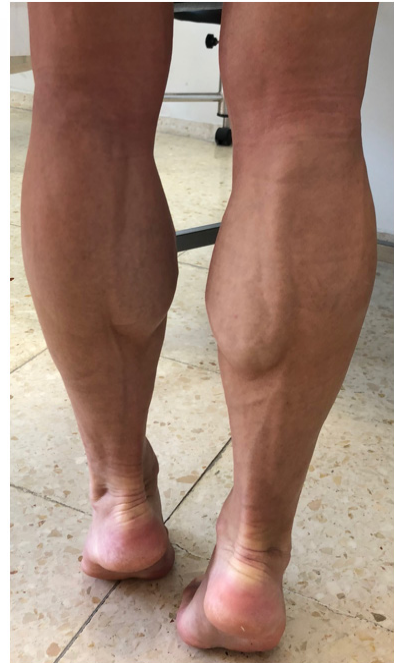Patients with FPLD type 2, in particular women, commonly present precocious insulin resistance [Araújo-Vilar 2003], which can occasionally be associated to acanthosis nigricans and acrochordons (Fig. 13), and which may lead to nonketotic diabetes in adulthood. Hypertriglyceridemia is frequent and may be severe,

leading occasionally to episodes of acute pancreatitis. However, in our experience, lifestyle, particularly diet, has a big influence on the appearance of these complications. Furthermore, HDL cholesterol is normally low. Fatty liver disease is common and is generally associated with high plasma levels of aminotransferases, with infrequent liver cirrhosis [Lüdtke 2005]. Affected women present gynaecological disorders such as PCOS, gestational diabetes, miscarriages, and foetal death [Vantyghem 2008] and a higher risk of cardiovascular disease [Hegele 2001], as well as muscular pain [Bidault 2011]. The presence of subcutaneous lipomas, albeit not in all patients, could lead the clinician to suspect Dunnigan disease in the context of an FPLD phenotype (Figure 14) [Araújo-Vilar 2012].

The cardiovascular spectrum of this lipodystrophy is broad, including early atherosclerotic cardiovascular disease, alterations in the heart rate, valvulopathies and hypertrophic cardiomyopathy [Hegele 2001, Vantyghem 2004, Araújo-Vilar 2008, Bidault 2013, Andre 2015]. Alterations in the heart rate are more frequent in these cases due to variants in LMNA other than codon Arg482 [Kwapich 2018].



**Figure 10.** Patient with Dunnigan disease



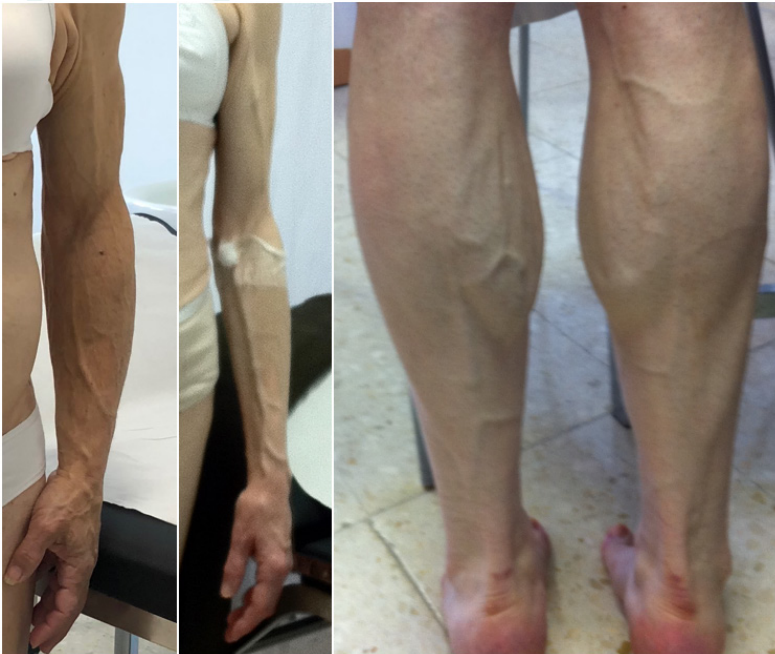**Figure 11.** Hypertrophy of the calves in a patient with Dunnigan disease



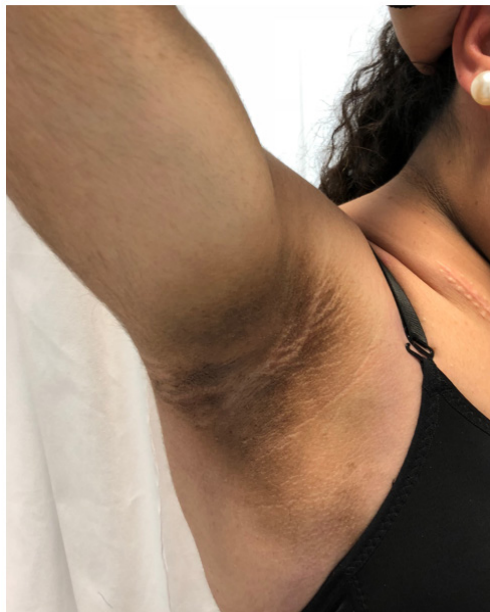The prevalence of metabolic alterations and atherosclerotic vascular disease is conspicuously more common in women than in men [Garg 2000]. On the other hand, there has been a recent report of an anticipation phenomenon in relation to the metabolic complications of Dunnigan disease [Jeru 2017].

The family history (dominant vs. recessive) and certain phenotypical features and associated disorders (valvulopathies, myocardial hypertrophy and/or disorders of the cardiac conduction system) can guide the molecular diagnosis. Other laminopathies (Emery-Dreifuss muscular dystrophy, limb-girdle muscular dystrophy and familial dilated cardiomyopathy) can also be associated with FPLD type 2 or may even be present in other members of the family [Subramanyam 2010, Guillín-Amarelle 2018b]. Therefore, a thorough cardiac and muscular evaluation is recommended, even of family members with no evident phenotype. Variants in exons other than 8 in LMNA may lead to atypical forms of FPLD type 2, in which the lipodystrophy is less evident, or can even be confused with Köbberling syndrome.

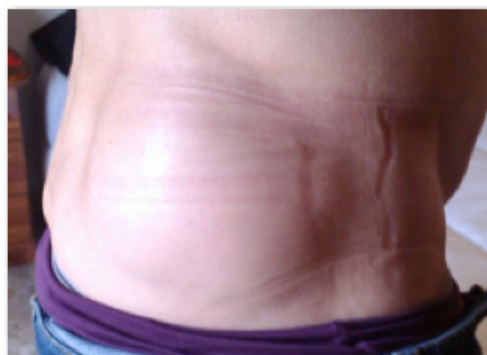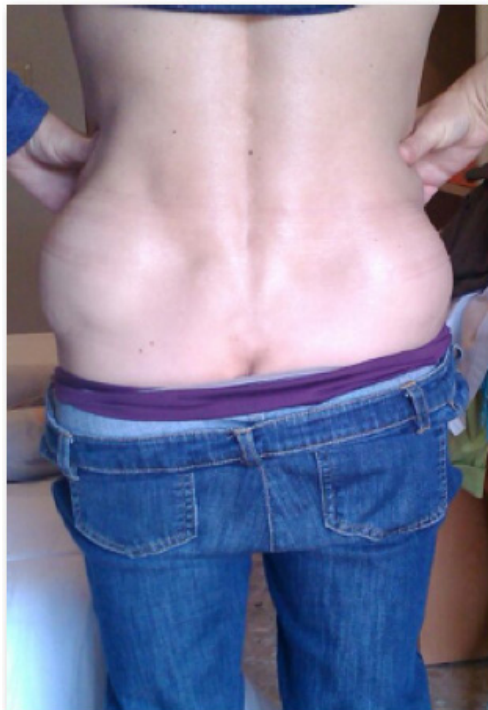Leptin serum levels tend to be low in the familial partial lipodystrophies, although no specific threshold has been defined as a diagnostic criterion [Brown 2016].



**Figure 12.** Flebomegaly in a female patient with Dunnigan disease



**Figure 13.** Acanthosis nigricans in a patient with Dunnigan disease



**Figure 14.** Lipomas in a patient with Dunnigan disease



**FPLD type 3** (MIM: #604367) [Barroso 1999, Agarwal 2002] follows an autosomal dominant inheritance pattern. The lipoatrophy appears during adolescence or in early adulthood, affecting the limbs, buttocks and hips. Although it is not always the case, there may be an accumulation of fat in the face, neck and suprascapular region, as well as in the abdominal region. Muscular hypertrophy has also been described, particularly in the forearms and calves, along with amenorrhea, hirsutism and acanthosis nigricans. Severe and badly-controlled hypertension may also occur and eclampsia in pregnancy, [Al-Shali 2004, Hegele 2006, Francis 2006, Auclair 2013]. Cardiometabolic complications are normally severe [Semple 2006]. However, differentiating characteristics include the presence of some subcutaneous fat in the upper arms, without phlebectasia and a less prominent musculature in the arms and calves.

**FPLD type 4** (MIM: #613877), associated to variants in the *PLIN1* gene, follows an autosomal dominant pattern of inheritance. Lipoatrophy appears in childhood or in adulthood with the possible accumulation of facial fat. These patients also present insulin-resistant diabetes, acanthosis nigricans, severe hypertriglyceridemia, hypertension and fatty liver disease [Gandotra 2011]. The lipoatrophy predominantly affects the gluteal region and the lower limbs, although a reduction in subcutaneous adipose tissue in the trunk and upper limbs has also been observed. These patients also present muscular hypertrophy, which is more notable in the lower limbs. Their facio-cervical adipose tissue may be normal, although 2 patients have had a Cushingoid appearance. Two patients have presented ovarian dysfunction, with chronic oligomenorrhea and hyperandrogenaemia, respectively.

FPLD types 5 and 6 are recessive disorders with only a few cases having been notified. FPLD type 5 (MIM: #615238) appears in early childhood, while type 6 does so in adulthood.

To date, only one case of **FPLD type 5**, due to a variant in the *CIDEA* gene, has been published [Rubio-Cabezas 2009]. In this patient, the absence of fat deposits in the buttocks, hips and lower limbs and the preservation of visceral, neck and axillae fat and muscular lower limbs were observed by way of magnetic nuclear resonance. The patient presented acanthosis nigricans and diabetes mellitus prone to ketosis, along with severe dyslipidaemia with hypertriglyceridemia and secondary pancreatitis and hepatomegaly in relation to fatty liver disease.

FPLD type 6 (MIM: #615980) [Farhan 2014, Carboni 2014, Zolotov 2017] is a late-onset (2<sup>nd</sup>-3<sup>rd</sup> decade) partial lipodystrophy due to biallelic variants in the *LIPE* gene which is associated with multiple lipomatosis and with abnormal ac-



cumulations of fat in the neck, supraclavicular area, axillae, the area below the triceps, back, abdomen and labia majora. The lipoatrophy mainly affects the buttocks, hips and lower limbs. Strikingly, these patients may present progressive muscular dystrophy which manifests itself as proximal weakness in the lower limbs, although it can also affect the shoulder girdle and lead to an increase in creatine kinase and dystrophic changes in the muscular biopsy. As in the rest of the FPLDs, diabetes mellitus, hypertriglyceridemia and fatty liver disease appearing in adulthood are not uncommon. Ophthalmological investigations revealed numerous auto-fluorescent drusen-like retinal deposits in all patients [Sollier 2020].

**FPLD associated to PCYT1A** follows an autosomal recessive inheritance pattern [Payne 2014] and only 2 cases have been described to date. The onset of the phenotype is precocious, during childhood, with lipoatrophy affecting the arms, legs and buttocks, and the preservation of fat in the trunk, dorsocervical and submandibular regions and in the mons pubis and labia majora. Unlike other subtypes of FPLD, this subtype presents with short stature and muscular atrophy. Diabetes secondary to insulin resistance appears in the second decade of life. These patients present hypertriglyceridemia, low concentrations of HDL cholesterol, hypertransaminasemia and severe fatty liver disease.

**FPLD associated to ADRA2A** follows an autosomal dominant inheritance pattern [Garg 2016] and, to date, 3 patients have been identified as belonging to the same pedigree. The disorder appears in adolescence and is characterised by a marked loss of subcutaneous fat in the upper and lower limbs (including the soles of the feet), in the anterior region of the trunk and hips, as well as in the cranium and the orbits. Furthermore, these patients present an increase of fat in the face and neck, both in the anterior and posterior regions, in the posterior cervicothoracic region and the intra-abdominal region, whereas perirenal and posterior intraperitoneal fat is preserved. They also present muscle hypertrophy in the limbs and acanthosis nigricans. Metabolic complications (diabetes and dyslipidaemia) and arterial hypertension appear in the 3<sup>rd</sup>-4<sup>th</sup> decade of life. The oldest patient studied also presented hirsutism, oligomenorrhea and precocious cardiovascular disease.

**FPLD associated to MFN2** [Sawyer 2015, Rocha 2017, Capel 2018] is an autosomal recessive disorder beginning in childhood or adolescence associated to the variant p.Arg707Trp in the mitofusin-2 protein in homozygosis or compound heterozygosis. It is characterised by the presence of lipomatous masses in the upper part of the body, which may be large in size and can compromise the respiratory tract, associated to a loss of adipose tissue in the gluteofemoral region,



forearms and lower limbs. It is also frequently associated to early-onset peripheral axonal neuropathy and secondary contractures in the feet.

Women may present primary amenorrhea in relation with hypogonadotropic hypogonadism, delayed bone age, delay in the development of secondary sexual characteristics and small uterus.

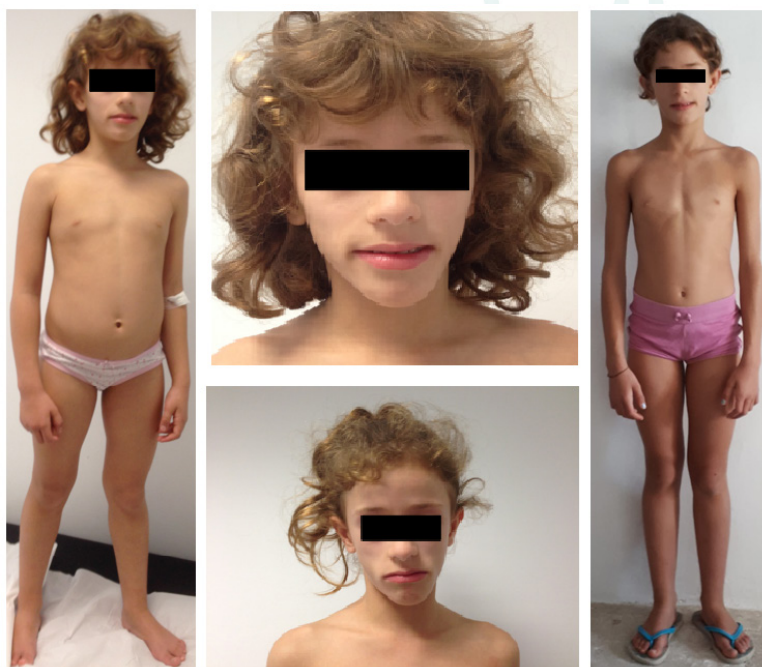Other clinical characteristics which may be present include greater musculature in the limbs, phlebomegaly, extremely increased appetite, male-pattern hair growth, acanthosis nigricans, and cramps in the legs after exercise and burning and tingling sensations in the hands and feet. Metabolically, they present insulin resistance with hyperinsulinemia and hypertriglyceridemia with low HDL cholesterol. In spite of the fact that these patients are of normal weight or are obese, leptin and adiponectin plasma levels are extremely low.

## 11. ACQUIRED PARTIAL LIPODYSTROPHIES

### 11.1 Acquired Partial Lipodystrophy (APL) or Barraquer-Simons syndrome

Barraquer-Simons syndrome is an extremely rare disorder of unknown (possibly autoimmune) aetiology, characterised by a cephalocaudal loss of SAT. It is more common in women than in men (relation 4:1) (Fig. 15), and the fat loss generally begins in childhood or adolescence, sometimes following a viral infection. The fat loss initially affects the head, giving children an aged appearance, advancing towards the scapular girdle, the upper limbs and trunk [Brown 2016] in a process which may last weeks, months or years. When an affected woman gains weight, she accumulates fat in the hips and lower limbs, presenting a unique APL phenotype. Fat deposits in the breasts and different areas of the body have also been described. The fat in the gluteal region, bone marrow, orbits and mediastinal region is not affected. Intermuscular, intraperitoneal and perirenal fat is also normal. The arms have well-defined musculature and apparent phlebomegaly. Acanthosis nigricans is generally absent [Misra 2004]. Although the aetiology of APL is unknown, the presence of other autoimmune diseases may be of help in confirming the diagnosis, particularly membranoproliferative glomerulonephritis (MPGN), which may cause kidney failure [Brown 2016].

Although it has historically been considered that metabolic complications are not particularly relevant in this subtype of lipodystrophy [Misra 2004], a recent study suggests that these complications have been underestimated [Akinci 2015]. Patients tend to have low serum levels of complement C3 and leptin and the C3 nephritic factor is detectable [Misra 2004].



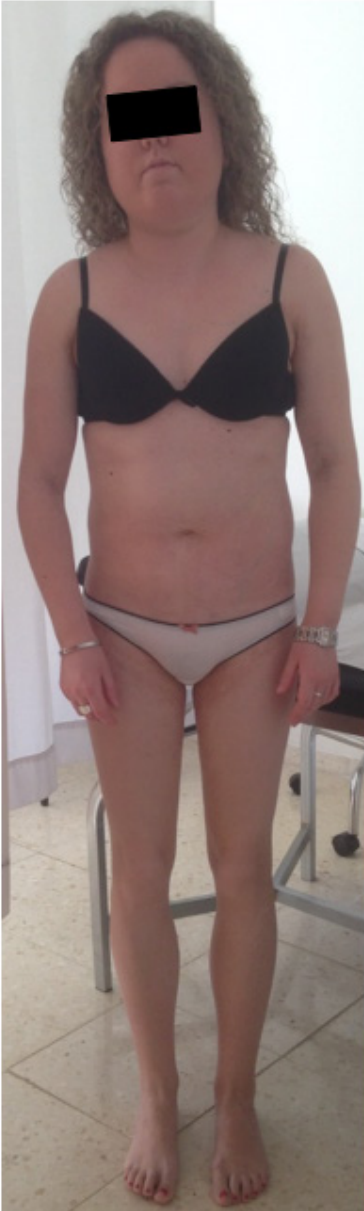**Figure 15.** Patient with Baraquer-Simons syndrome

As mentioned above, a characteristic feature of this condition is its association with MPGN, which affects approximately a third of patients (Misra, 2004). In general, these patients do not present clinical evidence of kidney disease or anomalies in kidney function until 10 years after the beginning of the loss of adipose tissue. Autoimmune diseases and antinuclear and anti-DNA antibodies have been detected in several patients. Morbidity and mortality in this disorder is fundamentally related with kidney impairment and the autoimmune diseases with which it is often associated.

### **11.2. Partial lipodystrophy associated to hematopoietic stem cell transplantation in childhood**

Several reports have described a pattern of abnormal subcutaneous and visceral fat among patients subjected to whole body radiotherapy, including survivors of childhood cancer (leukaemia, retinoblastoma) and those who have received hematopoietic stem cell transplantation [Adachi 2013, Wei 2015, Adachi 2017]. This lipodystrophy is added to the high risk of developing endocrinopathies and metabolic disorders such as delayed complications following hematopoietic stem





cell transplantation. Due to the low lean mass of the patients, this syndrome is known as “lipodystrophic and sarcopenic” [Adachi 2013]. In these patients, lipotrophy is notable in the gluteal regions and in the limbs, whereas fat is preserved in the cheeks, neck and abdomen. This is associated with a greater deposition of visceral fat, insulin resistance and hypertriglyceridemia. These characteristics are similar to those of FPLD (Fig. 16).

**Figure 16.** Patient with partial lipodystrophy associated with hematopoietic stem cell transplantation



## 12. COMPLEX SYNDROMES

Complex lipodystrophic syndromes are those in which the lipoatrophy is just one more component (not necessarily the most relevant one) of a constellation of signs and symptoms reflecting alterations in different tissues, organs and systems and which commonly present dysmorphic characteristics. They include the premature ageing syndromes and certain autoinflammatory syndromes.

## 13. PREMATURE AGEING SYNDROMES (Progerias)

The progeroid syndromes are characterised by the presence of general premature ageing stigmas, such as alopecia, greying, osteoporosis, joint contracture, a variable degree of lipodystrophy, loss of muscle mass and senile changes in the skin, among others [Conneely 2012, Lessel 2015 Carrero 2016] (Table 4).

**Table 4.** Signs suggestive of premature ageing conditions

---

|                               |
|-------------------------------|
| Delayed development           |
| Short stature                 |
| Alopecia                      |
| Premature greying             |
| Bulging eyes                  |
| Cataracts                     |
| Micrognathia                  |
| Sensorineural hearing loss    |
| Dental crowding               |
| Sharp/bulbous nose            |
| High-pitched, nasal voice     |
| Taut skin, dry, with wrinkles |
| Sclerodermiform lesions       |
| Leukomelanodermic macules     |
| Ungueal dysplasia             |
| Sloping shoulders             |
| Acroosteolysis                |
| Osteopenia-osteoporosis       |
| Joint contractures            |
| Low muscle mass               |

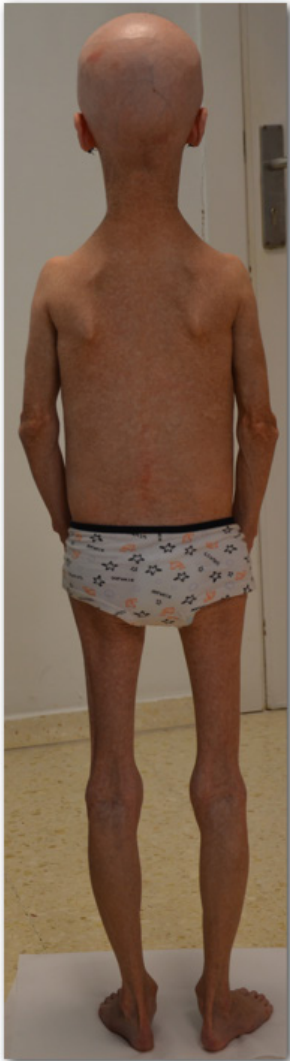---



Certain characteristics, such as short stature, alopecia, grey hair, sclerodermiform changes in the skin, cutaneous atrophy, ungueal dystrophy, osteoporosis, acro-osteolysis, joint contractures, small jaw, dental crowding, low muscle mass and mottled pigmentation of the skin, among others, are highly suggestive of premature ageing syndromes [Hennekam 2006].

### 13.1. Progerias associated to generalised lipotrophy

#### *Hutchison-Gilford syndrome*



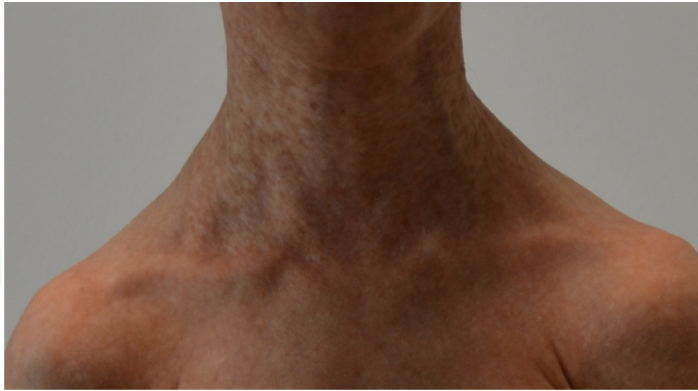The phenotypical characteristics of Hutchinson-Gilford progeria (HGPS) (MIM: #176670) are similar independently of sex and ethnicity. This disease is due to de novo heterozygous variants in LMNA gene, being one of the most frequent a single-base substitution, a C-to-T transition resulting in a silent gly-to-gly change at codon 608 within exon 11 (p.(G608G)). Patients are normal at birth, with the particular physical appearance beginning to become evident at 18-24 months and including a wide range of signs and symptoms [Hennekam 2006, Mazereeuw-Hautier 2007, Merideth 2008]: delayed growth, short stature, low body weight, incomplete (prepubertal) sexual development, a disproportionately large head with and high-arched palate, sharp nose, micrognathia, nasal or high-pitched voice, circumoral cyanosis, osteolysis of the mandible and dental crowding, generalised lipodystrophy which preserves intra-abdominal fat, acroosteolysis, osteopenia and osteoporosis, reduced muscle mass and joint stiffness with restricted mobility (Fig. 17). The skin becomes thinner and sclerotic, with many leukomelanodermic macules (Fig. 18) and prominent vasculature. Additional clinical characteristics are sensorineural conductive or high frequency hearing loss, premature alopecia with the absence of eyebrows and eyelashes, prominent veins in the scalp and ungueal dystrophy (Fig. 19). Malign neoplasms are not typical in HGPS.

**Figure 17.** Patient with Hutchinson-Gilford Progeria

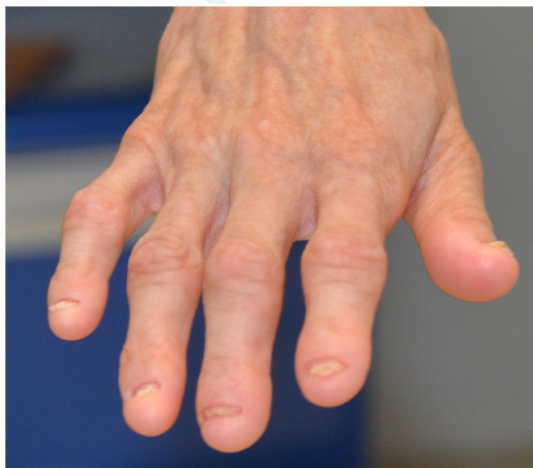

Biochemical exams may show prolonged prothrombin time, high platelet counts and high levels of serum phosphorous. Fasting insulin values may be high and, at times, associated to nonketotic diabetes and hypertriglyceridemia [Merideth 2008].

There is evidence of the thickening of the arterial adventitia in patients with HGPS, along with low vascular “compliance”. These patients suffer arterial hypertension, which leads to biventricular hypertrophy and biatrial enlargement [Merideth 2008]. Cardiovascular disease (stroke, myocardial infarction) is a cause of premature death, with an average life expectancy of 13.4 years (7-27.5) [Hennekam 2006, Merideth 2008].



**Figure 18.** Leukomelanodermic macules in a patient with Hutchinson-Gilford Progeria



**Figure 19.** Ungueal Dystrophy in a patient with Hutchinson-Gilford Progeria



### ***Néstor-Guillermo Progeria***

This progeria (MIM: #614008) owes its name to Néstor and Guillermo, two patients aged 31 and 24 years of age, from two unrelated Spanish families. The disorder is defined as a secondary laminopathy. It originates from a homozygous missense variant in the BANF1 gene, the gene which codes the Barrier to Autointegration Factor (BAF), a protein which mediates the interactions between the nuclear lamins and chromatin throughout the cell cycle [Cabanillas 2011].

The affected patients presented normal development until the age of two. Subsequently, they demonstrated a development failure with a peculiar appearance including characteristics of ageing: micrognathia, convex nasal crest, proptosis, atrophic skin with senile spots, generalised lipoatrophy with flebomegaly. They suffered from osteoporosis, evident scoliosis from the age of 18 and severe osteolysis of the lower jaw, upper jaw, clavicles, ribs and distal phalanges. Unlike patients with HGPS, both of these patients were taller (145 cm) and preserved the hair on their eyebrows, eyelashes and scalp, at least until the age of 12. However, the two defining factors between these disorders are a much longer life expectancy and the absence of atherosclerosis and metabolic syndrome. Indeed, some experts call it “chronic progeria” due to its slow progression and longer life expectancy. However, the patients presented secondary pulmonary hypertension and a severe restrictive spirometry pattern with biatrial enlargement. Analytical studies only revealed a lack of vitamin D2 and severe hypoleptinemia. Unlike HGPS and MAD, these patients did not present metabolic alterations, fatty liver disease or atherosclerosis [Cabanillas 2011, Puente 2011].

### ***Mandibuloacral dysplasia type B***

Mandibuloacral dysplasia (MAD) is an extremely rare autosomal recessive disorder which appears in early childhood (2-4 years) and is characterised by multiple musculoskeletal anomalies and progeroid characteristics. There are two types of MAD: A (partial loss of fat in the limbs with the preservation of fat in the neck and trunk) and B (generalised). MAD can be attributed to variants in the LMNA gene (type A) [Novelli 2002] (see below) or in the ZMPSTE24 gene (type B) [Agarwal 2003b, Ben Yaou 2011]. Some 30 patients have been reported with MADA, whereas the number of those with MADB does not reach a dozen [Garg, 2011, Vantighem 2012, Worman 2009].

The phenotype of MADB (MIM: #608612) appears at birth with postnatal growth retardation and difficulties in feeding, being premature birth not infrequent. These children have a small chin, sharp nose, small mouth, dental crowding

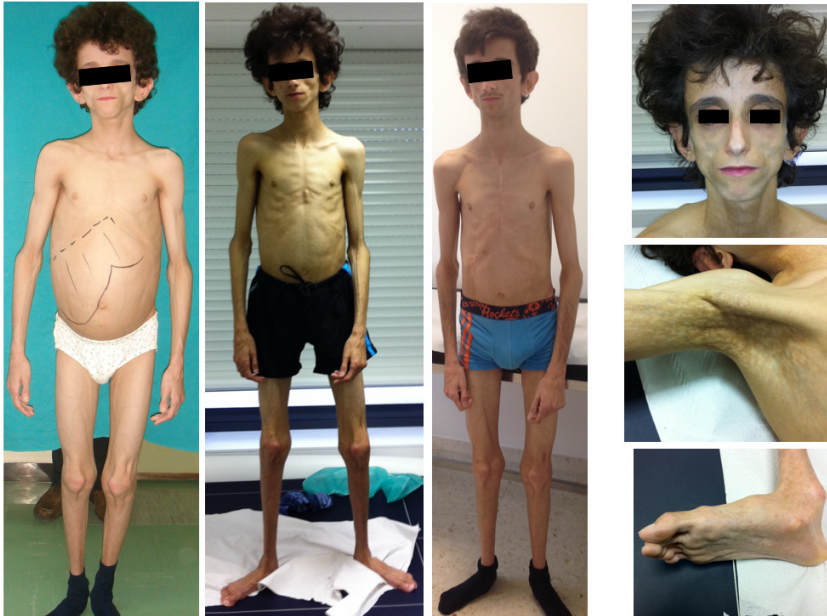

and retrognathia. In addition, they present contractures due to their taut skin. Other typical features include pigmented cutaneous marks, delayed closure of the fontanelles, the persistence of Wormian bones [Bertrand 2011], small hypoplastic clavicles, progressive distal osteolysis of the phalanges and clavicles and other ageing stigmas such as sensorineural hearing loss and hair loss. One differential factor of this progeroid syndrome is the presence of sclerotic calcified subcutaneous nodules, the absence of acanthosis nigricans, kidney disease (glomerulopathy) and a generalised pattern of lipodystrophy [Schrandner-Stumpel 1992, Simha 2002, Ben Yaou 2011]. Glucose tolerance is normal, although there is postprandial and fasting hyperinsulinemia, hypertriglyceridemia and low levels of HDL cholesterol [Simha 2003b].

### ***Atypical progeroid syndromes***

Some heterozygous missense and, generally, de novo variants, in the LMNA gene give rise to other subtypes of premature ageing which are different to classical HGPS. Lipodystrophy is present in all cases, albeit to differing degrees, ranging from generalised to partial forms affecting only the distal extremes of the limbs. The clinical characteristics of these disorders coincide in some cases with other disorders related with LMNA variants, such as HGPS, FPLD2, MAD, Emery-Dreifuss muscular dystrophy and familial dilated cardiomyopathy, which would suggest that these independent clinical conditions are, in reality, different forms of presentation of the same disorder, modulated by unknown (endogenous and/or exogenous) factors. Furthermore, the same variant may cause different clinical features.

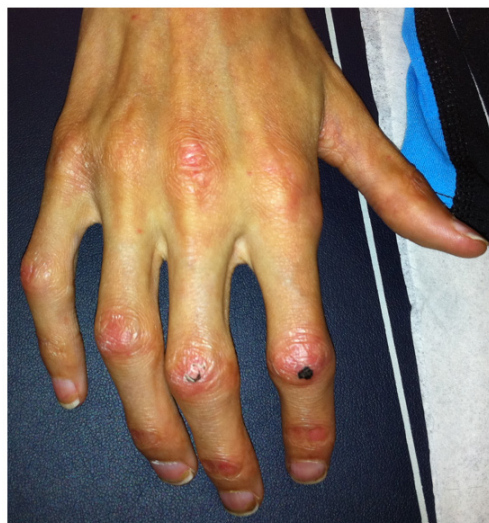Therefore, the atypical progeroid syndromes (APS) constitute a small set of disorders which are due to heterozygous missense variants in the LMNA gene, with a slightly delayed onset of clinical manifestations when compared with HGPS and MAD (Fig. 20) [Garg 2009, Guillín-Amarelle 2015]. Likewise, the patients appear to live longer, even more than 50 years [Motegi 2014].



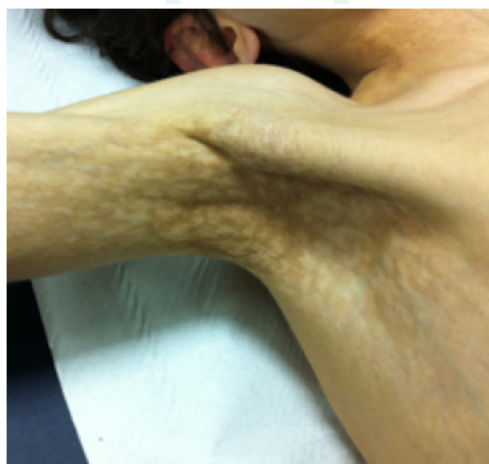**Figure 20.** Patient with atypical progeroid syndrome

Clinically, these disorders are clearly heterogeneous, but they share several common characteristics with the other premature ageing syndromes, such as greying hair, sensorineural hearing loss in some cases, sclerotic skin (Fig. 21) with leukomelanodermic lesions (Fig. 22), joint stiffness, alopecia (sometimes slight or absent), small jaw, abnormal implantation of the teeth with crowding, high-arched palate and sharp nose [Csoka 2004, Doubaj 2012]. However, unlike MAD and HGPS, in APS acroosteolysis is absent or slight, affecting only the distal phalanges, the same occurs with clavicular hypoplasia [Garg 2009]. Curiously, although menstrual cycles are normal, hypoplastic breasts are common in women with APS. Premature ovarian failure has only been reported in a few cases [Garg 2009] or proteinuric nephropathy [Magno 2020].

On a cardiovascular level, severe anomalies are common in the heart valves, including mitral, aortic and, sometimes, tricuspid insufficiency, as well as aortic stenosis; but also dilated cardiomyopathy and rhythm disorders [Magno 2020]. Patients may have to undergo a heart transplant due to dilated cardiomyopathy [Hussain 2018]. As far as the type of lipodystrophy in APS is concerned, it can be generalised (with or without an excess of visceral fat) or partial, and can be associated to diabetes, hypertriglyceridemia and fatty liver disease with hepatomegaly. In general, the metabolic alterations are worse than those observed



**Figure 21.** Sclerodermiform lesions in a patient with atypical progeroid syndrome



**Figure 22.** Leukomelanodermic macules in a patient with atypical progeroid syndrome

in HGPS and MAD and, strikingly, acanthosis nigricans uses to be absent [Csoka 2004, Mory 2008].

Recently, a premature ageing syndrome has been reported associated to variants in codon 55 (exon 1) in the LMNA gene [Soria-Valles 2016]. The clinical presentation of this atypical neonatal progeria associated to LMNA, reported in three children, recapitulates that of patients with HGPS and MAD. However, the symptoms appear early in life, the lipodystrophy can be generalised or partial and the prognosis is poor in relation to the obstructive apnoea associated with retrognathia and stroke.

Finally, dilated cardiomyopathy with hypergonadotropic hypogonadism is an atypical form of late-onset HGPS due to missense variants in the LMNA gene (p.(A57P) and p.(L59R)) (MIM: #212112) [McPherson 2009]. It is characterised by the presence of dilated cardiomyopathy, early ovarian failure, generalised lipodystrophy associated with insulin resistance and progressive facial and skeletal changes (clavicular hypoplasia, low bone density). Unlike the classical form, patients do not suffer distal acroosteolysis, alopecia, severe growth failure or marked atherosclerosis. In this case, intellectual disability may be present (9-25%).





### ***MDPL Syndrome***

MDPL (mandibular hypoplasia, deafness, progeroid features, and lipodystrophy syndrome) (MIM: #615381) is an autosomal dominant disorder caused by de novo variants in the POLD1 gene and is characterised by mandibular hypoplasia, deafness, progeroid features, general lipodystrophy and, in males, hypogonadism [Weedon 2013]. The illness usually appears in early childhood with poor growth and thin limbs caused by the loss of subcutaneous adipose tissue. Sensorineural deafness usually appears when the child is between 6 and 18 years of age. Facial characteristics of the disorder include an aquiline nose, prominent eyes, dental crowding and a small mouth. Some patients have presented a more generalised loss of subcutaneous fat, even in the face and neck, which tends to increase with age. The marked decrease in subcutaneous fat contrasts with a significant increase of visceral adipose tissue. All of the affected individuals have shown clinical and biochemical evidence of insulin resistance despite having a low BMI. More variable characteristics include an enlarged liver, telangiectasia, scleroderma, skin atrophy and cataracts, as well as ligament contractures, osteoporosis, kyphosis/scoliosis, a decrease in muscle mass in the limbs and, in males, hypogonadism and undescended testicles. Many of the characteristics are reminiscent of mandibuloacral dysplasia, although acroosteolysis, clavicular hypoplasia and thinning hair are not observed in these patients [Shastry 2010].

### ***Marfan syndrome with lipodystrophy similar to neonatal progeroid syndrome***

This is an autosomal dominant disorder (MIM: #616914) caused by de novo variants in the FBN1 gene [O'Neill 2007, Graul-Neumann 2010, Takenouchi 2013, Passarge 2016].

The lipoatrophy is generalised and is already apparent at birth. This generalised loss of subcutaneous fat is similar to CGL, although, in some patients, the pattern presented a decrease in subcutaneous fat in the paravertebral region, the lateral gluteal region, the face and the distal parts of the hands and feet, with a marked decrease in the amount of intra-abdominal and intramuscular fat. As opposed to CGL, which is associated with muscular hypertrophy, patients with this disorder also have a concomitant loss of muscle mass which can contribute to their extremely thin appearance. In addition, these patients present prominent veins, possibly due to dermal hypoplasia.

These patients have a progeroid appearance from the moment of their birth, with a prominent forehead, scaphocephaly with an open anterior fontanelle, sharp



nose, high narrow palate and retrognathia, low-set ears, long arms and legs, arachnodactyly and arthrogryposis, particularly in the lower limbs. In addition, they may exhibit proptosis, pectus excavatum and acute bilateral myopia. Their posture may be slightly kyphotic without scoliosis but with winged scapulae. They may also have slight hypermobility of the finger joints.

No significant metabolic abnormalities have been detected in these patients, apart from slight to moderate hypertriglyceridemia which is usually transitory, hyperinsulinemia with standard fasting plasma glucose and normal levels of A1c haemoglobin. These patients did not exhibit signs of fatty liver disease, splenomegaly, atherosclerosis or polycystic ovarian syndrome. Their mental and motor development are within normal limits.

The clinical signs associated with Marfan syndrome vary. While joint hypermobility, arachnodactyly and acute myopia are common, other signs such as ectopia lentis, dilation of the aortic arch, mitral valve prolapse, and lumbosacral dural ectasia are only present in some patients.

### ***Cockayne syndrome***

Cockayne syndrome (MIM: #216400, #133540) is a multisystem developmental disorder, with a non-uniform clinical phenotype [Nance 1992] and is considered to be a progeria. Many of the clinical characteristics, including early-onset neurodegeneration, leading to intellectual disability, and the appearance of the skin, are similar to those of accelerated ageing. This autosomal recessive disorder is due to biallelic variants in the ERCC6 or ERCC8 genes [Licht 2003, Henning 1995]. This diagnosis should be suspected in any child with postnatal growth failure, microcephaly and any two of the following characteristics: persistently cold hands and feet, bilateral deafness, increased sensitivity to sunlight, joint contractures, a progressive loss of body fat, cataracts and characteristic facial features. The average age of death for patients with this syndrome is 8.4 years old, with the death usually being caused by progressive neurodegeneration.

These patients may exhibit progressive retinopathy, atrophy of the optic disc, miotic pupils or decreased tearing, dental caries, a characteristic physical appearance (“cachectic dwarfism”), with ambulatory patients having a characteristic posture.

Less common symptoms include hypertension, renal dysfunction, an enlarged liver and/or an increase in serum transaminases, undescended testicles and anhidrosis.



### ***Keppen-Lubinsky syndrome***

This syndrome is an autosomal recessive disorder caused by biallelic variants in the KCNJ6 gene [Masotti 2015] associated with generalised lipodystrophy (MIM: #614098).

These patients present severe developmental delays, intellectual disability, hypertension, hyperreflexia, growth below the 5<sup>th</sup> percentile at the age of 6-9 months, microcephaly, large protruding eyes, a narrow nasal bridge, a tented upper lip, high-arched palate, open mouth, tightly adherent skin and an aged appearance.

### ***Ruijs-Aalfs syndrome***

Ruijs-Aalfs syndrome (MIM: #616200) is an autosomal recessive disorder caused by biallelic variants in the SPRTN gene [Lessel 2014].

Patients with this disorder have delayed growth, a short stature, lipodystrophy, muscular atrophy and signs of premature ageing. Death often occurs before the age of 20 as a result of hepatocellular carcinoma. Key clinical signs of the disorder include cataracts, premature greying of the hair, small eyes, a bulbous nose with a high nasal bridge, small upper lip and skeletal abnormalities such as micrognathia, a small frontotemporal diameter, sloping shoulders, kyphoscoliosis, slight pectus excavatum, moderate bilateral elbow contractures, bilateral clinodactyly and flat feet.

## **13.2. Progerias associated with partial lipodystrophy**

### ***Mandibuloacral dysplasia type A***

Mandibuloacral dysplasia type A (MADA, MIM: #248370) is an extremely rare autosomal recessive disorder (homozygous or compound heterozygous) caused by variants in the LMNA gene.

MADA can be diagnosed in patients between childhood and puberty (at the age of 5 on average) due to their short stature and particular phenotypic characteristics, which include a pointed nose, high-arched palate, sparse hair, craniofacial anomalies such as mandibular hypoplasia and dental crowding, sloping shoulders, osteoporosis, progressive osteolysis of distal bones, persistently widened cranial sutures, multiple Wormian bones, abnormal skin pigmentation and joint stiffness. Curiously, over time the osteolysis can extend to other parts of the skeleton, such as the elbows [Young 1971, Novelli 2002, Kosho 2007, Guglielmi 2010].



The lipodystrophy pattern is partial and is associated with extreme insulin resistance and marked hypermetabolism [Freidenberg 1992]. Patients show a normal tolerance to glucose but may experience postprandial and fasting hyperinsulinemia and hypertriglyceridemia with low levels of HDL. In addition, in some cases, premature adrenal cortical dysfunction, which is typical of normal ageing, has been observed [Ng 2000].

### ***Werner syndrome***

Werner syndrome [Yu 1996] (MIM: #277700) is caused by homozygous or compound heterozygous variants in the RECQL2 gene, which codes a nuclear exonuclease.

The typical phenotype of Werner syndrome begins progressively in the first or second decade of life which is why it can be considered as a late onset progeroid syndrome [Hegele 2007]. These patients have a short stature, a bird-like face with a beaked nose, high-pitched voice, cataracts, premature greying of the hair, cutaneous signs of scleroderma and osteoporosis. In addition, these patients present lipodystrophy affecting the face and limbs and a thick trunk which is associated with insulin resistance and diabetes, hypogonadism (gonadal atrophy), muscular atrophy of the limbs, calcification of blood vessels, senile dementia and premature death (in the 3<sup>rd</sup>-4<sup>th</sup> decade of life) related to cardiovascular disease or cancer. Malignancy is frequent among patients with this disorder (10%) [Goto 1996], with non-epithelial cancers (osteosarcoma, soft tissue sarcoma, melanoma) being more common than in the general population.

### ***SHORT syndrome***

SHORT (MIM: #269880) is an acronym for S = stature; H = hyperextensibility or hernia (inguinal) or both; O = ocular depression; R = Rieger anomaly; T = teething delay. In this autosomal dominant syndrome, the non-progressive lipodystrophy principally manifests as a lack of subcutaneous fat in the face, chest, arms (though not the legs), a generally thin stature and, sometimes, a local loss of fat which causes small pits in the skin on the elbows and buttocks [Koenig 2003]. All patients who have suffered this disorder have typically had a shorter stature in comparison to the rest of their family. Other physical characteristics of these patients include a triangular face, prominent forehead, deep-set eyes, hypertelorism, hypoplasia or narrow nasal wings, a small chin and large auricles. Hypoplasia of the middle third of the face gives the impression that these patients have apparent prognathism despite the fact that they exhibit micrognathia. They also have delayed bone age and hypotrichosis [Aarskog 1983]. Their thin and wrinkled skin and visible veins also intensify the impression of progeria



[Koenig 2003]. Rieger anomaly can appear at birth with congenital glaucoma and clouding of the cornea or the complete absence of the stroma of the iris. In spite of delayed speech development in childhood, the patient's mental state will appear to be normal or only slightly below normal [Gorlin 1975]. This disorder is caused by a heterozygous variant in the PIK3R1 gene [Thauvin-Robinet 2013].

Metabolically, these patients may present with nonketotic diabetes mellitus with insulin resistance [Aarskog 1983, Schwingshandl 1993, Avila 2016].

In 2008, Reardon and Temple described two patients suffering from nephrocalcinosis in childhood. These patients also exhibited an increase in serum and urinary calcium, suggesting that their altered calcium metabolism could be a characteristic of SHORT syndrome.

In 2016, after examining the clinical characteristics of 32 patients diagnosed with SHORT, Avila et al. concluded that the principal characteristics of the disorder included lipoatrophy and insulin resistance, and that the minor characteristics of SHORT syndrome should include delayed tooth development, wrinkled skin, delayed speech or language development, sensorineural deafness, joint hypermobility and inguinal hernias.

### ***Bloom syndrome***

Bloom syndrome (MIM: #210900) is a paediatric autosomal recessive disorder caused by variants in the RECQL3 gene, which codes RecQ helicase [Ellis 1995]. This syndrome is characterised by impaired growth, telangiectasis, altered skin pigmentation, photosensitivity, hypertrichosis, polydactyly, a predisposition to malignancy and chromosomal instability. Lipodystrophy affects the patients' limbs and abdomen and they may also present diabetes.

### ***Fontaine progeroid syndrome***

Fontaine progeroid syndrome [Fontaine 1977] is an autosomal dominant disorder caused by variants in the SLC25A24 gene [Ehmke 2017] (MIM: #612289). This is probably the same disorder as Petty progeroid syndrome.

Patients with this disorder exhibit delayed prenatal and postnatal growth, an aged appearance characterised by a loss of subcutaneous fat, wrinkled skin and prominent veins, a large anterior fontanelle, an abnormal hair pattern on the scalp, facial dysmorphisms (such as a triangular face, convex nasal bridge, prominent or deep-set eyes, low-set ears) and small nails and distal phalanges, particularly in the sides of the ulna and fibula. Furthermore, two individuals suffered from craniosynostosis [Writzl 2017]. Most patients with this disorder die prematurely.



### ***Neonatal progeroid syndrome***

This disorder, also known as Wiedemann-Rautenstrauch syndrome, follows a pattern of autosomal recessive inheritance. Its molecular basis is unknown, although it has been suggested that the syndrome could be caused by alterations to the functioning of the A subunit of the RNA polymerase III (POLR3A) [Paolacci 2017]. Children affected by this disorder are characterised by their delayed intrauterine and postnatal growth, short stature, progeroid appearance with cranial deformations, hypotonia, variable mental deterioration and death in infancy [Hegele 2007]. The lipodystrophy is almost generalised and, in some cases, a paradoxical accumulation of fat around the buttocks, anogenital region and sides has been reported [Arboleda 1997, O'Neill 2007]. Recently [Garg 2015], two variants in the CAV1 gene were identified in two patients with some characteristics similar to those of neonatal progeroid syndrome. However, these patients had surpassed the average age of death for people suffering from this disorder.

## **14. AUTOINFLAMMATORY SYNDROMES**

The autoinflammatory syndromes which cause lipodystrophy include Nakajo-Nishimura syndrome, JMP syndrome (joint contractures, muscular atrophy, microcytic anaemia and panniculitis-induced lipodystrophy) and CANDLE syndrome (chronic atypical neutrophilic, dermatosis with lipodystrophy and elevated temperature). These disorders begin in childhood and the lipodystrophy can be generalised or partial, affecting the face and limbs. All of the above are recessive disorders related to variants in genes coding proteins which are essential for the maturation and assembly of proteasomic subunits [Agarwal 2010, Arima 2011, Kluk 2014].

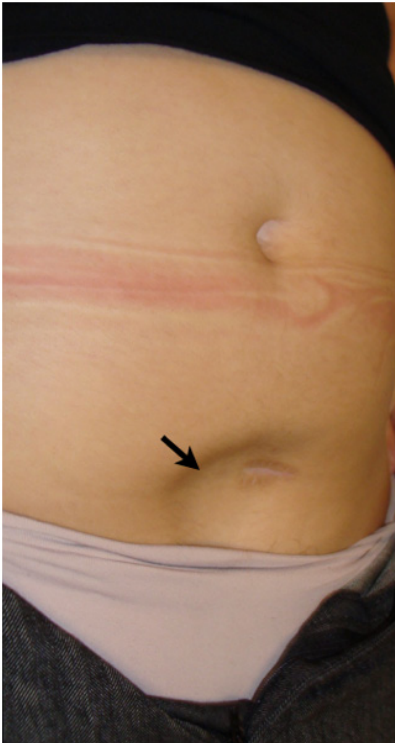Nakajo-Nishimura syndrome is an inflammatory condition that includes lipomuscular atrophy and joint contractures [Arima 2011]. As its name suggests, JMP syndrome is characterised by joint contractures, muscular atrophy, microcytic anaemia and panniculitis-induced lipodystrophy [Garg 2010]. Other characteristics include intermittent fever, hypergammaglobulinemia, an increase in sedimentation rate, hepatosplenomegaly and calcification of the basal ganglia. Patients with CANDLE syndrome present with recurrent fever in childhood and violaceous annular plaques on the eyelids and lips, evolving during childhood towards a loss of subcutaneous fat in the face and arms. These patients also suffer from hepatosplenomegaly, arthralgia, microcytic anaemia, an increase in sedimentation rate and calcifications in the basal ganglia [Torrelo 2010].



## 15. LOCALISED LIPODYSTROPHY

These types of lipodystrophy are characterised by a loss of subcutaneous fat in a small area of the body, as opposed to the generalised or partial (but not localised) forms of lipodystrophy described previously in this guide.

### *Localised lipodystrophy caused by drugs*



**Figure 23.** Localised lipoatrophy as a result of insulin injections.

Some patients with diabetes have reported abnormal reactions to medication in their subcutaneous fat, principally when injecting insulin [Radermecker 2007]. Injected insulin can cause lipohypertrophy (the lipomatous development caused by the lipogenic effect of insulin) or lipoatrophy, which is considered as an adverse immunological side effect of the insulin [Peteiro-González 2011]. Lipoatrophy induced by the injection of insulin typically occurs in children and young patients with type 1 diabetes (Fig. 23). Lipoatrophy has become increasingly uncommon with the availability of newer insulin analogues, whilst lipohypertrophy is still prevalent [Hussein 2007]. In addition, it has been reported that injectable pegvisomant, a growth hormone receptor antagonist which is used to treat acromegaly, may cause lipohypertrophy in the abdominal wall, in the site of the injections, in some patients [Bonert, 2008]. These localised lipodystrophies generally resolve themselves spontaneously and are not associated with systemic disorders. Educating patients about rotating

their injection sites and changing the injection area seems to be the best way of avoiding localised lipodystrophy as a result of insulin or pegvisomant injections in affected patients.

Localised subcutaneous lipoatrophy is also a common adverse effect of the repeated injection of intramuscular corticosteroids [Hamidou et al., 1991; Avilés-Izquierdo et al., 2006] and usually clears up on its own. However, cosmetic treatment with poly-L-lactic acid [Brodell and Marchese Johnson, 2014] or hyaluronic acid fillers [Di Gregorio, 2016] has been reported.



### ***Lipoatrophia semicircularis***

Lipoatrophia semicircularis is a rare pathology characterised by semi-circular depressions in the subcutaneous adipose tissue in the anterolateral areas of the thighs [Hodak 1990]. This condition mainly affects office workers and it is considered to be an occupational disease. The skin and underlying muscles remain intact. The origin of this particular form of lipoatrophy is unknown but it has been suggested that it is caused by repeated mechanical microtraumas and localised pressure on the affected muscles, even including electromagnetic fields influence [Linares-García 2015], although the latter does not seem plausible. Reports published regarding lipoatrophia semicircularis principally concern women and it has been proposed that the anatomical composition of the adipose tissue in women's thighs is predisposed to having a persistent mechanical pressure originating from impaired circulation in perfused tissue, which induces the development of this type of lipoatrophy [Herane 2007]. Recent studies have stated that avoiding exposure to mechanical pressure (edges of office desks) reduces the occurrence of new cases, as well as the recovery of affected people [Reinoso-Barbero 2013].

### ***Centrifugal lipodystrophy***

Centrifugal lipodystrophy (“lipodystrophia centrifugalis abdominalis infantilis”) is a localised form of lipodystrophy which affects small children. Most patients reported are Japanese, Korean or Chinese, although some cases of Caucasian patients have been recorded [Imamura, 2012]. Patients generally exhibit depressed lesions in the groin and axilla, with a loss of subcutaneous adipose tissue, often surrounded by slight erythema during the first 3-4 years of life. The depressed lesions gradually expand centrifugally until they affect the patient's abdominal or chest wall. In most cases, this expansion usually ceases spontaneously after a few years and most patients demonstrate spontaneous improvement after the expansion stops and before reaching adulthood. The aetiopathology of this alteration is unknown.

### ***Panniculitis-associated lipodystrophy***

This is a rare condition, also known as lipoatrophic panniculitis and annular lipoatrophic panniculitis of the ankles [Shen 2010, Corredera 2011], in which inflammatory panniculitis is associated with localised permanent lipoatrophy in children [Peters 1980]. Circumferential bands of lipoatrophy have been observed on the arms and legs of patients, or scattered depressions in the subcutaneous adipose tissue, preferably located in the extremities (Fig. 24). The causes of this





disorder are unknown, but it has been associated with autoimmune disorders. It has been hypothesised that the inflammatory signals arise locally from the fat cells targeted by the panniculitis, thereby encouraging the lipoatrophy [Levy 2017].

## 16. MANAGEMENT AND MONITORING OF PATIENTS WITH LIPODYSTROPHY

Recently, a free app for diagnosis of rare lipodystrophies (LipoDDx<sup>®</sup>) has been developed by investigators from the University of Santiago de Compostela, both for IOSs or Android smartphones [Araujo-Vilar 2020].

Distinguishing between congenital and acquired lipodystrophy [Brown 2016]

The analysis of a patient's genetic history can reveal whether their lipodystrophy is congenital or acquired. Examination of childhood photographs can help to distinguish CGL from AGL as babies typically exhibit an absence of fat if they are suffering from CGL types 1 or 2, whilst they exhibit normal amounts of fat if they suffer from AGL. However, there have been reports of some cases of AGL with a loss of fat during the first few months of life [Misra 2003]. Patients with AGL do not usually have a family history of the disorder but it can be confused with any other type of congenital lipodystrophy, especially those caused by de novo genetic variants. The presence of signs suggesting premature aging (Table 4) should point towards a genetic cause.

The presence of autoimmune disorders (myositis, type 1 diabetes, autoimmune hepatitis and others) [Garg 2004, Misra 2004, Pope 2006, Savage 2009, Safar Zadeh 2013] increases the suspicion of acquired lipodystrophy. With APL, low concentrations of complement C3, the presence of C3NeF, proteinuria or MPGN proven with a biopsy would support the diagnosis.

### ***Genetic studies***

Genotyping can include only a limited number of gene sequences, a panel of candidate genes or the full sequencing of the exome/genome. In Spain, the National Health System allows genetic studies to be carried out through the National Centre for Genome Mapping (CeGen) ([www.usc.es/cegen](http://www.usc.es/cegen)). CeGen is a technological platform created in 2003 which is currently part of the Online platform of Biomolecular and Bioinformatic Resources (PRB3) of the Carlos III Health Institute (ISCIII) (CeGen-ISCIII). CeGen-ISCIII consists of two genome mapping hubs, one located at the University of Santiago de Compostela ([56](http://www.</a></p></div><div data-bbox=)



xenomica.eu) and the other at the National Cancer Research Centre (Madrid). As the result of collaboration between the Lipodystrophy Unit of the Department of Endocrinology and Nutrition of the University Hospital Complex of Santiago de Compostela and the Galician Foundation of Genomic Medicine, an NGS panel was developed which includes 25 genes involved in the aetiology of the congenital lipodystrophies (Table 5). Since there is strong evidence of additional loci for congenital lipodystrophy, negative testing results cannot exclude a congenital condition.

### ***Genetic counselling and detection in family members***

Genetic counselling must take into account the fact that current understanding of the natural history of the congenital lipodystrophies is incomplete. For affected families, preconception counselling with genetic testing to detect the status of the carrier must be considered.

In Spain, individuals carrying both dominant and recessive variants who wish to have children must be made aware of the possibility of having a preimplantation genetic diagnosis. In addition, pregnant women, whether they are carriers or have a disorder, can find out if they will pass their disorder on to any offspring and, if this is the case, they must be informed of their right to a voluntary termination of the pregnancy.

The clinical diagnosis of lipodystrophy in men can be difficult [Garg 2000], with some genotypes being associated with phenotypes of mild lipodystrophy [Savage 2004, Decaudain 2007]. Genetic detection in members of the family can help to identify people with subtle phenotypes. This genetic detection can be of particular importance for families with specific variants in the LMNA gene associated with cardiomyopathy and arrhythmia or with some variants in the BSCL2 gene with risk of Celia's encephalopathy.



**Table 5.** List of genes included in the lipodystrophy panel produced by the Galician Foundation of Genomic Medicine

---

ADR2A  
 AGPAT2  
 AKT2  
 BANF1  
 BLM  
 BSCL2  
 CAV1  
 CIDEC  
 ERCC6  
 ERCC8  
 FBN1  
 KCNJ6  
 LIPE  
 LMNA  
 MFN2  
 PCYT1A  
 PIK3R1  
 PLIN1  
 POLD1  
 PPARG  
 PSMB8  
 PTRF  
 WRN  
 SPRTN  
 ZMPSTE24

---

***Study of comorbidities***

The levels of scientific evidence are based on the criteria of the American Heart Association [Gibbons 2003] (Table 6).



**Table 6.** System of evaluation of evidence of the American Heart Association

---

Classification

I: Intervention is useful and effective

IIa: The weight of evidence/opinion is in favour of the usefulness/effectiveness

IIb: Usefulness/effectiveness is less well established for the evidence/opinion

III: The intervention is not useful/effective and could be harmful

---

Level of evidence

A: Sufficient previous evidence from multiple randomised trials

B: Limited evidence from one randomised trial and other non-randomised trials

C: Based on expert opinion, case studies or standards of care

---

All patients should undergo exams used to detect diabetes, dyslipidaemia, NASH, and cardiovascular and reproductive dysfunction. As patients with APL have a lower risk of metabolic complications, clinical judgement must guide the follow-up. The screening processes for all comorbidities specific to all individual subtypes of lipodystrophy will not be discussed in detail in this guide.

Diabetes mellitus

1. Tests for the detection of diabetes must be carried out each year (Class IIa, Level C).

The tests for detecting diabetes must follow the guidelines set out by the American Diabetes Association (fasting plasma glucose levels, oral glucose tolerance test (OGTT) or haemoglobin A1c). Patients with AGL may develop type 1 diabetes mellitus as well as insulin resistance [Park 2008]. The measuring of autoantibodies can clarify the diagnosis.

Dyslipidaemia

1. Triglycerides must be measured at least once a year or more frequently if the patient experiences abdominal pain or eruptive xanthomata (Class I, Level C)
2. A fasting lipid profile (10-12 hours) (total cholesterol, LDL cholesterol, HDL cholesterol, triglycerides) should be obtained at the moment of diagnosis and each year after the patient passes the age of 10 (Class IIa, Level C)



### Liver disease

1. Alanine aminotransferase (ALT) and aspartate aminotransferase (AST) should be measured annually (Class IIa, Level C).
2. A liver ultrasound must be carried out at the moment of diagnosis, and at other times depending on the criteria of the medical team (Class IIa, Level C).
3. A liver biopsy must be carried out in accordance with the criteria of the medical team. (Class IIa, Level C).

In addition to physical examination, ultrasound and liver elastography are useful for calculating the size of the liver and spleen, the severity of the steatosis and fibrosis and for detecting the existence of portal hypertension. Patients with CGL type 2 have a higher risk of developing premature cirrhosis and those with AGL may develop autoimmune hepatitis in addition to NASH [Safar Zadeh 2013].

### Reproductive disorders

1. Gonadal steroids, gonadotrophins and pelvic ultrasounds should be carried out depending on the criteria of the medical team (Class IIa, Level C)
2. Pubertal staging must be carried out each year for children (Class IIa, Level C)

Premature adrenarche, premature puberty or central hypogonadism can occur in children with generalised lipodystrophy. Oligo-amenorrhoea, a decrease in fertility and PCOS are common in women with lipodystrophy.

### Heart disease

1. Blood pressure must be taken at least once a year (Class I, Level C)
2. An electrocardiogram and echocardiogram must be carried out once a year for patients with CGL, at the moment of diagnosis for patients with progeroid syndromes and at other times in accordance with the criteria of the medical team for patients with FPLD and AGL (Class IIa, Level C)
3. Assessment of ischemic cardiopathy and heart rate monitoring should be considered in patients with progeroid syndromes and in patients with FPLD type 2 with cardiomyopathy (Class IIa, Level C)

Hypertension is common [Brown 2015], even in children. Patients with CGL type 4, atypical progeroid syndromes or FPLD type 2 may exhibit cardiac abnormalities, including ischemic cardiopathy, cardiomyopathy, arrhythmias and sudden death [Rheuban 1986, Bhayana 2002, Caux 2003, Decaudain 2007, Araújo-Vilar 2008, Khalife 2008, Ben Turkia 2009, Lupsa 2010, Debray 2013, Andre 2015].



### Nephropathy

1. The patient's proteinuria must be measured annually either as albuminuria in 24-hour urine collection test or as a ratio of albumin to creatinine (Class IIa, Level C)

Proteinuria is common [Javor 2004]. A renal biopsy should be carried out according to the criteria of the medical team. The pathology may include diabetic nephropathy, focal and segmental glomerulosclerosis (especially in patients with CGL) [Javor 2004] or MPGN (especially in patients with APL) [Misra 2004].

### Cancer

Lymphomas, particularly peripheral T-Cell lymphoma, may occur in patients with AGL with a prevalence of 7% [Misra 2003, Brown 2015b]. Although a consensus regarding a screening process has not been reached, it seems reasonable to include an annual examination of the skin and lymph nodes. It has been reported that generalised lipodystrophy has been seen as a paraneoplastic manifestation of pilocytic astrocytoma in three children who regained their body fat after undergoing therapy for this type of tumour [Patni 2015]. Bearing this in mind, doctors should consider testing to detect brain tumours in children with idiopathic AGL and atypical CGL. Certain progeroid syndromes (e.g. Bloom and Werner syndrome) are associated with a greater risk of developing cancer.

## 17. TREATMENT

### ***General considerations***

The mainstays of treatments for lipodystrophy have been compiled in The Diagnosis and Management of Lipodystrophy Syndromes: A Multi-society Practice Guideline [Brown 2016] published in the J. Clin. Endocrinol. Metab. in 2016. The levels of scientific evidence are based on the criteria of the American Heart Association [Gibbons 2003] (Table 6).

Lipodystrophy syndromes are progressive and potentially fatal conditions. **There is currently no cure for lipodystrophy** and there is no treatment for regenerating adipose tissue. Metabolic comorbidities must be treated in order to manage the complications of the illness in the short to long term.

### ***Diet*** [Brown 2016]

1. The majority of patients should follow diets with a balanced composition of macronutrients (Class IIa, Level C)



2. Low-calorie diets improve metabolic abnormalities and may be suitable for adults (Class I, Level C)
3. Patients suffering from acute hyperchylomicronaemia-induced pancreatitis should follow very low-fat diets (Class I, Level C)
4. An endocrinologist should be consulted if the patient has special dietary requirements, particularly if the patient is a baby or small child. **Overfeeding must be avoided** (Class IIa, Level C)
5. Medium-chain triglyceride (MCT) oil formulas can provide energy and reduce triglycerides in babies (Class IIa, Level C)

**The cornerstone of treatment for the metabolic complications of lipodystrophy is the patient's diet.** There are insufficient studies into specific diets for lipodystrophy patients and recommendations are based on the scarce literature that exists and on clinical experience.

Patients with lipodystrophy, especially in its generalised forms, usually suffer from hyperphagia as a result of leptin deficiency. Energy-restricted diets for adolescents and adults reduce triglycerides and glucose levels [Robbins 1979], but it is difficult to manage dietary restrictions. The restriction of foodstuffs to control metabolic complications should be balanced with what children need to eat in order to grow correctly. **Overfeeding to achieve a normal weight can worsen metabolic complications and fatty liver disease.** The assessment of height/weight and body mass index (BMI) in comparison with the growth reference data is not appropriate in these cases due to the fact that the body composition of the patient is atypical. A low weight for the patient's height or a low BMI would be acceptable as long as the patient's growth remains linear.

Patients should follow a diet consisting of 50-60% carbohydrates, 20-30% fats and 20% proteins. Simple sugars should be restricted and there should be a preference for complex carbohydrates with a high fibre content, distributed evenly between meals and snacks and eaten in combination with proteins and/or fats. Dietary fats should mainly consist of monounsaturated fats and long-chain omega-3 fatty acids. In severely hypertriglyceridemic children, MCT-based formulas may be beneficial [Glueck 1977, Wilson 1983]. Patients suffering from acute pancreatitis should make use of bowel rest followed by an extremely low-fat diet (20 g).

A more extended dietary recommendations are compiled in González-Rodríguez et al. [2020].

**Physical exercise** [Brown 2016]

1. Patients with lipodystrophy should be encouraged to exercise whenever there are no specific contraindications (Class IIa, Level C)
2. Patients with subtypes of lipodystrophy which make them more prone to cardiomyopathy must undergo a cardiac evaluation before starting an exercise regime (Class III, Level C)

People with lipodystrophy who do intense exercise have experienced improvements in their metabolic complications. The majority of patients should be encouraged to be physically active. However, strenuous exercise must be avoided by patients with cardiomyopathy. Patients with severe hepatosplenomegaly and those with CGL with lytic bone lesions should avoid contact sports.

**Recombinant human leptin (metreleptin)** [Brown 2016]

According to The Diagnosis and Management of Lipodystrophy Syndromes: A Multi-society Practice Guideline, metreleptin is suitable in the following situations:

1. For patients with generalised lipodystrophy. Metreleptin (along with diet) is a first-line treatment for metabolic and endocrine abnormalities (Class I, Level B), and can be an option for the prevention of these comorbidities in children (Class IIb, Level C)
2. For hypoleptinemic patients (leptin <4 ng/mL) with partial lipodystrophy and severe metabolic disorders (HbA1c >8% and/or triglycerides > 500 mg/dL) metreleptin treatment could be considered. (Class IIb, Level B)

Currently, metreleptin (recombinant methionyl human leptin) is the only medication specifically approved for lipodystrophy. It has been approved in the USA as a dietary supplement for the treatment of metabolic complications in patients with generalised lipodystrophy

([www.accessdata.fda.gov/drugsatfda\\_docs/label/2015/125390s010lbl.pdf](http://www.accessdata.fda.gov/drugsatfda_docs/label/2015/125390s010lbl.pdf)).

In Japan it has been approved for the treatment of both generalised and partial lipodystrophy

([www.shionogi.co.jp/en/company/news/2013/pmrltj0000000ufd-att/e\\_130325.pdf](http://www.shionogi.co.jp/en/company/news/2013/pmrltj0000000ufd-att/e_130325.pdf)).

In 2018, the European Medicines Agency approved the use of metreleptin in adults and children over the age of 2 with generalised lipodystrophy (Berardinelli-Seip syndrome and Lawrence syndrome), and in adults and children over





the age of 12 with partial lipodystrophy (including Barraquer-Simons syndrome) when standard treatments have failed.

([www.ema.europa.eu/ema/index.jsp?curl=pages/medicines/human/medicines/004218/human\\_med\\_002251.jsp&mid=WC0b01ac058001d124](http://www.ema.europa.eu/ema/index.jsp?curl=pages/medicines/human/medicines/004218/human_med_002251.jsp&mid=WC0b01ac058001d124)).

Table 7 shows a dosing algorithm [Meehan 2016]. Adjustments to the dosage should be made in response to metabolic parameters and to any changes in weight with a clinical and laboratory assessment being performed every 3-6 months.

**Table 7.** Recommended dosage of metreleptin

| Reference weight     | Initial daily dosage (injection volume) | Dosage adjustment (injection volume)         | Daily maximum dosage (injection volume) |
|----------------------|---|--|---|
| Women and men ≤40 kg | 0.06 mg/kg<br>(0.012 ml/kg)             | 0.02 mg/kg<br>(0.004 ml/kg)                  | 0.13 mg/kg<br>(0.026 ml/kg)             |
| Men >40 kg           | 2.5 mg<br>(0.5 ml)                      | from 1.25 mg (0.25 ml)<br>to 2.5 mg (0.5 ml) | 10 mg<br>(2 ml)                         |
| Women >40 kg         | 5 mg<br>(1 ml)                          | from 1.25 mg (0.25 ml)<br>to 2.5 mg (0.5 ml) | 10 mg<br>(2 ml)                         |

### Metreleptin in generalised lipodystrophy

Metreleptin decreases hyperphagia [Oral 2002, Moran 2004, McDuffie 2004, Musso 2005, Ebihara 2007], which frequently leads to weight loss.

The reduced intake of foodstuffs is at least partially responsible for many of the metabolic improvements. If the patient experiences excessive weight loss, the dosage of metreleptin should be reduced [Meehan 2016].

Metreleptin has been proved to significantly improve fasting glucose levels from the first week of use [Ebihara 2007] and to reduce HbA1c levels by 2% after a year of use [Diker-Cohen 2015]. A significant reduction of A1c has been proved during more extended periods of time [Brown 2018]. In order to reduce the risk of hypoglycaemia, the frequent monitoring of glucose levels is recommended. Doctors should consider reducing the dosage of insulin by 50% at the start of the treatment with metreleptin for patients with well-controlled diabetes. Many young patients with CGL may stop using insulin altogether [Diker-Cohen 2015]. Metreleptin reduces triglycerides after a week of use [Ebihara 2007] and can achieve a reduction of 60% after a year [Diker-Cohen 2015]. Metreleptin also reduces LDL cholesterol and total cholesterol, although it has no effect on HDL



cholesterol [Chong 2010, Chan 2011]. It has been reported that some patients who suddenly stop taking metreleptin or reduce their dosage suffer episodes of acute pancreatitis due to severe hypertriglyceridemia [Chan 2011].

Metreleptin reduces fatty liver disease, serum transaminases and NASH scores in the first 6 to 12 months of treatment [Petersen 2002, Simha 2003c, Javor 2005, Ebihara 2007]. In one case, metreleptin reduced the recurrence of severe fatty liver disease following a liver transplant [Casey 2013].

In the majority of patients, metreleptin decreases proteinuria [Javor 2004, Ebihara 2007]. However, four patients experienced a worsening of kidney disease during treatment with metreleptin. Therefore, the kidney function of patients with pre-existing nephropathy must be closely monitored [Javor 2004].

In women, metreleptin normalised the secretion of gonadotrophins, which results in the normal progression of puberty, the normalisation of menstrual periods [Oral 2002, Musso 2005, Ebihara 2007, Abel 2016] and an improvement in fertility [Brown 2016]. Metreleptin decreases testosterone levels in women but it does not alter their ovarian morphology [Oral 2002, Musso 2005, Lungu 2012]. In men, metreleptin increases testosterone levels [Musso 2005].

Leptin replacement therapy has also been associated with a decrease in liver volume and serum levels of aminotransferases [Oral 2002, Javor 2005, Chan 2011]. Paired biopsy studies have shown that NASH associated with CGL improves with metreleptin treatment [Javor 2005, Safar Zadeh 2013]. During 52 weeks of treatment with metreleptin, improved brain connectivity associated with the hedonic and homeostatic control of eating behaviour, a decrease in appetite and an increase in satiety was observed [Schlogl 2016].

A recent study [Brown 2018] assessed the effectiveness and safety of metreleptin in 66 patients with generalised lipodystrophy at 4, 12 and 36 months. The study found that there were significant reductions in HbA1c levels (-2.2%) and fasting glucose levels (-54 mg/dL) and an average percentage change in fasting triglyceride levels of -32.1% from the start of month 12. The reductions over time compared to the initial value of these parameters were also significant in month 36. In month 4, 34.8% of patients experienced a reduction of  $\geq 1\%$  in HbA1c levels and 62.5% experienced a reduction of  $\geq 30\%$  in fasting triglycerides. In month 12, 80% of patients experienced a  $\geq 1\%$  decrease in HbA1c levels or a  $\geq 30\%$  decrease in triglycerides, and 66% of patients experienced a  $\geq 2\%$  decrease in HbA1c levels or a  $\geq 40\%$  decrease in triglycerides. Of the patients taking medication, 41% stopped taking insulin, 22% stopped taking oral antidiabetic medication and 24% stopped taking lipid lowering medication. The average decrease in liver volume in month 12 was 33.8%.



### Metreleptin in patients with partial lipodystrophy

The effects of metreleptin in patients with partial lipodystrophy is less clear than in patients with generalised lipodystrophy. In one study, metreleptin reduced hypertriglyceridemia and improved the blood sugar levels of patients with severe hyperleptinemia with partial lipodystrophy and severe metabolic disorders (HbA1c initial > 8%, triglycerides > 500 mg/dL, leptin <4 ng/ml) [Diker-Cohen 2015]. In a second study, metreleptin improved triglycerides, sensitivity and secretion of insulin indices in FPLD type 2 patients with moderate to severe hypoleptinemia [Vatier 2016]. However, in a third study, no improvements were observed in the blood sugar levels of patients with FPLD type 2 with leptin serum levels of <7 ng/ml [Simha 2012], although there was a decrease in levels of triglycerides in plasma. In another study, a small subset of patients with severe abnormalities (HbA1c  $\geq$  8.0% or triglycerides  $\geq$  500 mg/dL) who were treated with metreleptin for one year seemed to benefit substantially from the treatment in comparison with the total treated population [Ajluni 2016]. More recently, Oral et al. [2019] found significant reductions in HbA1c (-0.6%), fasting triglycerides (-20.8%) and liver volume (-13.4%) in partial lipodystrophy after 12 months of metreleptin treatment. The improvement in these parameters was maintained for longer periods (36 months) in those patients who noticed a better response during the first year. Metreleptin is only available for patients with partial lipodystrophy in Europe and Japan.

### Effectiveness of metreleptin in children with lipodystrophy

There is some evidence to suggest that metreleptin is effective in paediatric patients with generalised or partial lipodystrophy. Improvements in glycaemic levels, triglycerides, liver histology and markers of liver health were achieved over a year of treatment in 53 patients with generalised or partial lipodystrophy. These improvements were maintained for a period of five years as monitored by the USA National Institutes of Health [Brown 2017]. Metreleptin treatment did not accelerate or trigger puberty and it was associated with the normalisation of the growth of this group. However, only eight patients in this group had partial lipodystrophy, seven of whom were over the age of twelve, thereby limiting the generalisation of this intervention among young children.

### Side effects of and tolerance to metreleptin

Approximately 30% of patients experienced side effects [Chan 2011]. The most clinically relevant are hypoglycaemia (in patients who also take insulin) and reactions around the injection site (erythema, urticaria).



The in vitro neutralising effect of antibodies for leptin has been reported [Beltrand 2010, Chan 2016]. The clinical implications remain unclear, but they may include treatment failure and sepsis [Chan 2016]. Sometimes, patients treated with metreleptin show very high levels of serum leptin due to cross-reaction with anti-metreleptin antibodies, though this tends to reduce along time. This precludes the use of serum leptin as a way to dosage the drug. In our experience, at least 2 patients receiving metreleptin for more than eight years showed undetectable serum leptin levels despite maintaining an optimal metabolic control. The reason of this finding is unclear.

Additional severe adverse events which occurred during treatment with leptin are probably related to the subtype of lipodystrophy and not to the drug itself. These include T-cell lymphoma in patients with AGL [Brown 2015], pancreatitis and a worsening of liver [Chan 2011] and kidney disease [Javor 2004].

The development of lymphomas has been reported in patients with AGL regardless of whether they are being treated with metreleptin or not [Brown 2015]. The greater risk of malignancy in these individuals may be attributable to the autoimmune disease itself, although the theory that this drug may play a role in the development of tumours cannot be discounted [Brown 2015].

### **Treatment of diabetes mellitus** [Brown 2016]

1. Metformin is a first-line agent for diabetes and insulin resistance (Class IIa, Level C)
2. Insulin is effective for hyperglycaemia. In some patients, concentrated and high-dosage preparations may be required (Class IIa, Level C)
3. Thiazolidinediones can improve metabolic complications in patients with partial lipodystrophy (Class IIb, Level B)

Of all the oral hypoglycaemic agents, metformin is the one that is most commonly used. In Spain, metformin is only authorised for children over the age of 10, although, in our experience, this drug, which is administered for compassionate use, is tolerated well by children over the age of five at a dosage of 500-1000 mg b.i.d.. In patients with partial lipodystrophy, thiazolidinediones improve HbA1c levels, triglycerides, liver volume and steatosis, but they can also increase localised excesses of fat [Arioglu 2000, Victoria 2010, Luedtke 2012]. Pioglitazone is not authorised in Spain for use by patients under the age of 18, nevertheless it can be prescribed for compassionate use with a dosage of 15-30 mg q.d. for children with generalised lipodystrophy and a severe insulin resistance as there have been no reported side effects apart from nausea and headaches [Ghaleiha



2015]. In patients with high insulin requirements, concentrated insulin should be considered [Lane 2009]. Both insulin glargine and insulin degludec can be impaired when injecting into lipodystrophic areas as their prolonged action requires subcutaneous fat [Bolli 2000, Karges 2005], therefore, it would be better for these patients to use NPH insulin or insulin detemir.

Patients with generalised lipodystrophy may need to have intramuscular insulin injections if they do not have enough subcutaneous fat. Other hypoglycaemic agents have been used to treat lipodystrophy, but their effectiveness was referred to only a few cases [Kawana 2017, Oliveira 2017, Yamaguchi 2018].

### **Treatment of dyslipidemia** [Brown 2016]

1. Statins should be used concomitantly with changes to lifestyle (age, reproductive stage and tolerance must all be taken into consideration) (Class 1, Level C)
2. Fibrates and/or long-chain omega-3 fatty acids should be used for triglycerides >500 mg/dL, and can be considered for triglycerides >200 mg / dL (Class IIb, Level C)

Lipids should be managed in accordance with the guidelines issued by the USA and Europe for the general population, with statins used as a first-line treatment [Catapano 2011, Jellinger 2012, Stone 2014]. Statins and fibrates should be used with precaution due to the increased risk of myopathy, especially if there is a known presence of myositis or muscular dystrophy [Settergren 2013]. As the risk of cardiovascular disease can increase in patients with lipodystrophy syndromes independently of other risk factors, doctors may consider the application of stricter lipidic objectives (e.g., LDL cholesterol <100 mg/dL, non-HDL cholesterol <130 mg/dL, triglycerides <200 mg/dL), even in patients without diabetes. In addition to diet, fibrates and long-chain omega-3 fatty acids are widely used in clinical practice in order to avoid the serious complications of severe hypertriglyceridemia [Diker-Cohen 2015]. However, their use has not been formally studied. Plasmapheresis has been used in cases of extreme hypertriglyceridemia, but it must be repeated frequently [Bolan 2002]. Other lipid lowering drugs have not been studied in patients with lipodystrophy.

### **Treatment of hypertension** [Brown 2016]

1. Angiotensin-converting-enzyme inhibitors (ACE inhibitors) or angiotensin II receptor blockers (ARBs) are first-line treatments for hypertension in patients with diabetes. (Class IIa, Level C)



As in other patients with diabetes, ACE inhibitors or ARBs should be used to treat hypertension [American Diabetes Association].

### ***Treatment of liver disease*** [Brown 2016]

Cholic acid did not reduce hepatic steatosis in patients with FPLD in a double-blind, placebo-controlled crossover study [Ahmad 2013]. For patients with non-alcoholic steatohepatitis (NASH) not associated with lipodystrophy, diet and exercise are first-line treatments [Mitchel 2014]. Of the available pharmacological treatments, vitamin E (in children and adults) [Sanyal 2010, Lavine 2011] (73, 74) and pioglitazone (in adults) [Sanyal 2010, Boettcher 2012] have proven to be the most consistently beneficial for hepatic histopathology. However, these treatments have not been studied in patients with lipodystrophy.

### ***Treatment of Celia's encephalopathy***

There is no cure for Celia's encephalopathy. However, it has recently been published [Araújo-Vilar 2018b] that combining metreleptin with a diet low in saturated fats, rich in polyunsaturated fats and with a supplement of omega-3 fatty acids slowed down the neurological regression of one patient. In addition, an improvement in the brain's consumption of glucose was observed in a PET scan. These results were supported by in vitro studies of neurons treated with leptin and docosahexaenoic acid in which the expression of the aberrant BSCL2 was reduced by 30%. However, these results should be treated with extreme caution as they only reflect one case. Recently, treatment with metreleptin reduced the frequency of seizures in a patient with PELD [Pedicelli 2020].

### ***Cosmetic treatment*** [Brown 2016]

1. Patients should be evaluated for distress/anxiety related to their lipodystrophy and, if necessary, should be referred to a mental health professional and/or a plastic surgeon. (Class IIa, Level C).

The physical changes caused by lipodystrophy can cause anxiety and physical discomfort (e. g., due to an absence of fat pads on feet or buttocks). Data related to cosmetic surgery are limited. For facial lipoatrophy, autologous fat can be transferred to the face (in APL [Heidemann 2016]) or dermal fillers can be used [Graivier 2007, Garg 2011, Vallejo 2018]. Excesses of fat in the face, neck or vulva can be reduced either through surgery or via liposuction [Garg 2011]. Deoxycholic acid injection was approved in 2015 for the treatment of mild-to-moderate submental fat accumulation, but it has not been reported in familial partial lipodystrophy [Shridharani 2019]. Breast implants can be useful for some women



[Calderoni 2011, Hughes 2011]. Acanthosis nigricans can be improved by the successful treatment of insulin resistance [Eberling 2005, Araújo-Vilar 2015].

### **Contraception** [Brown 2016]

1. Oral oestrogens are contraindicated. (Class IIa, Level C)
2. If a contraceptive method is required, only progestin or non-hormonal contraceptives should be used. (Class IIa, Level C)
3. If oestrogen replacement is required, transdermal oestrogens should be employed. (Class IIa, Level C)

Oral oestrogens are contraindicated in patients with lipodystrophy due to the risk of severe hypertriglyceridemia and acute pancreatitis. Transdermal oestrogen may be safer as it reduces the liver's exposure to oestrogen [Walsh 1991]. There is clinical experience in the safe use of oral progestins and intrauterine devices which contain progestin.

### **Pregnancy and breastfeeding** [Brown 2016]

1. Pregnant patients should receive prenatal care from an obstetrician with experience in managing diabetes and a doctor with experience in managing lipodystrophy. (Class IIa, Level C)
2. If a patient becomes pregnant whilst taking metreleptin, her doctors may consider continuing with the medication if its suspension would pose a risk to the mother and/or fetus. The mother must also always be made aware and must understand that the effects of metreleptin on pregnancy are unknown (FDA category C) and they must confirm that they wish to continue the treatment. (Class IIc, Level C)

In lipodystrophy patients with extreme insulin resistance, a worsening of the resistance during pregnancy can make it difficult to control the diabetes and any consequent risks to the fetus. In addition, the withdrawal of metreleptin has been associated with rebound hypertriglyceridemia [Oral 2002], which puts the patient at risk of pancreatitis, thereby endangering both the mother and fetus.

### **Lipodystrophy Registry**

In the last few years, the European Consortium of Lipodystrophies ([www.eclip-web.org](http://www.eclip-web.org)), has launched the ECLip Lipodystrophy Registry (<https://epidem02.mezizin.uni-ulm.de:8080/login.xhtml>) with the aim of collecting clinical information of lipodystrophy patients for a long period of time, in order to study in deep



all of the issues related with epidemiology, natural history, associated co-morbidities, treatment response, mortality, psycho-social problems and health burden in these patients [von Schnurbein 2020]. At present, 18 groups from 11 countries are actively participating in this project.

### **CONFLICT OF INTERESTS**

D.A-V is a scientific advisor for Aegerion Pharmaceuticals and Amryt Pharma.

### **ACKNOWLEDGEMENTS**

We would like to thank the patients and their legal guardians for authorising the publication of the photographs in this guide.

D.A-V has received funding from the Carlos III Health Institute (PI081449, PI10/02873, PI13/00314, PI18/01890), the Galician Regional Government (PGIDIT03PXIB20801PR, PS09/17, 10PXIB2080-13PR, IN845B-2010/033, PGIDIT06PXIB208360PR, INCITE09E1R208068ES, GPC-2014/036, ED431B 2020/37), the Fundación Mutua Madrileña and the Association of Families and People Affected by Lipodystrophy (AELIP).





## 18. REFERENCES

Aarskog D, Ose L, Pande H, Eide N (1983). Autosomal dominant partial lipodystrophy associated with Rieger anomaly, short stature, and insulinopenic diabetes. **Am. J. Med. Genet.** 15: 29–38.

Abel BS, Muniyappa R, Stratton P, Skarulis MC, Gorden P, Brown RJ (2016) Effects of Recombinant Human Leptin (Metreleptin) on Nocturnal LH Secretion in Lipodystrophy Patients. **Neuroendocrinology** 103:402-7

Adachi M, Asakura Y, Muroya K, Goto H, Kigasawa H (2013) Abnormal adipose tissue distribution with unfavorable metabolic profile in five children following hematopoietic stem cell transplantation: a new etiology for acquired partial lipodystrophy. **Clinical Pediatric Endocrinology** 22: 53–64.

Adachi M, Oto Y, Muroya K, Hanakawa J, Asakura Y, Goto H (2017) Partial lipodystrophy in patients who have undergone hematopoietic stem cell transplantation during childhood: an institutional cross-sectional survey. **Clinical Pediatric Endocrinology** 26: 99–108.

Agarwal AK, Garg A (2002) A novel heterozygous mutation in peroxisome proliferator-activated receptor-gamma gene in a patient with familial partial lipodystrophy. **J Clin Endocr Metab** 87: 408-411.

Agarwal AK, Simha V, Oral EA, Moran SA, Gorden P, O’Rahilly S, Zaidi Z, Gurakan F, Arslanian SA, Klar A, Ricker A, White NH, Bindl L, Herbst K, Kennel K, Patel SB, Al-Gazali L, Garg A (2003) Phenotypic and genetic heterogeneity in congenital generalized lipodystrophy. **J Clin Endocrinol Metab** 88:4840–4847.

Agarwal AK, Fryns JP, Auchus RJ, Garg A (2003) Zinc metalloproteinase, ZMPSTE24, is mutated in mandibuloacral dysplasia. **Human Molecular Genetics** 12:1995–2001.

Agarwal AK, Xing C, DeMartino GN, Mizrahi D, Hernandez MD, Sousa AB, Martinez de Villarreal L, dos Santos HG, Garg A (2010) PSMB8 encoding the beta5i proteasome subunit is mutated in joint contractures, muscle atrophy, microcytic anemia, and panniculitis-induced lipodystrophy syndrome. **Am J Hum Genet** 87:866–872

Ahmad Z, Subramanyam L, Szczepaniak L, Simha V, Adams-Huet B, Garg A (2013) Cholic acid for hepatic steatosis in patients with lipodystrophy: a randomized, controlled trial. **Eur J Endocrinol.** 168:771–778.

Ajluni N, Dar M, Xu J, Neidert AH, Oral EA (2016) Efficacy and safety of metreleptin in patients with partial lipodystrophy: lessons from an expanded access program. **J Diabetes Metab** 7:659



Akinci B, Koseoglu FD, Onay H, Yavuz S, Altay C, Simsir IY, Ozisik S, Demir L, Korkut M, Yilmaz N, Ozen S, Akinci G, Atik T, Calan M, Secil M, Comlekci A, Demir T (2015) Acquired partial lipodystrophy is associated with increased risk for developing metabolic abnormalities. **Metabolism** 64:1086–1095

Al-Shali K, Cao H, Knoers N, Hermus AR, Tack CJ, Hegele RA (2004) A single-base mutation in the peroxisome proliferator-activated receptor gamma4 promoter associated with altered in vitro expression and partial lipodystrophy. **J Clin Endocrinol Metab** 89: 5655-60.

American Diabetes Association. Standards of Medical Care in Diabetes-2016 Abridged for Primary Care Providers. **Clin Diabetes** 34:3-21.

Andre P, Schneebeli S, Vigouroux C, Lascols O, Schaaf M, Chevalier P (2015) Metabolic and cardiac phenotype characterization in 37 atypical Dunnigan patients with non-farnesylated mutated prelamin A. **Am Heart J** 169: 587-93.

Araújo-Vilar D, Loidi L, Domínguez F, Cabezas-Cerrato J (2003) Phenotypic gender differences in subjects with familial partial lipodystrophy (Dunnigan variety) due to a nuclear lamin A/C R482W mutation. **Horm Metab Res** 35: 29-35.

Araújo-Vilar D, Lado-Abeal J, Palos-Paz F, Lattanzi G, Bandín MA, Bellido D, Domínguez-Gerpe L, Calvo C, Pérez O, Ramazanov A, Martínez-Sánchez N, Victoria B, Costa-Freitas AT (2008) A novel phenotypic expression associated with a new mutation in *LMNA* gene, characterized by partial lipodystrophy, insulin resistance, aortic stenosis and hypertrophic cardiomyopathy. **Clin Endocrinol (Oxf)** 69: 61-8.

Araújo-Vilar D, Victoria B, Gonzalez-Mendez B, Barreiro F, Fernandez-Rodriguez B, Cereijo R, Gallego-Escuredo JM, Villarroya F, Paneda-Menendez A (2012) Histological and molecular features of lipomatous and nonlipomatous adipose tissue in familial partial lipodystrophy caused by *LMNA* mutations. **Clin Endocrinol (Oxf)** 76:816–824.

Araújo-Vilar D, Sanchez-Iglesias S, Guillin-Amarelle C, Castro A, Lage M, Pazos M, Rial JM, Blasco J, Guillen-Navarro E, Domingo-Jimenez R, del Campo MR, Gonzalez-Mendez B, Casanueva FF (2015) Recombinant human leptin treatment in genetic lipodystrophic syndromes: the long-term Spanish experience. **Endocrine** 49: 139 –147.

Araújo-Vilar D, Santini F (2018) Diagnosis and treatment of lipodystrophy: a step-by-step approach. **J Endocrinol Invest**. Apr 27. doi: 10.1007/s40618-018-0887-z. [Epub ahead of print].

Araújo-Vilar D, Domingo-Jiménez R, Ruibal Á, Aguiar P, Ibáñez-Micó S, Garrido-Pumar M, Martínez-Olmos MÁ, López-Soler C, Guillín-Amarelle C, González-Rodríguez



M, Rodríguez-Núñez A, Álvarez-Escudero J, Liñares-Paz M, González-Méndez B, Rodríguez-García S, Sánchez-Iglesias S (2018) Association of metreleptin treatment and dietary intervention with neurological outcomes in Celia's encephalopathy. **Eur J Hum Genet.** 26:396-406.

Arima K, Kinoshita A, Mishima H, Kanazawa N, Kaneko T, Mizushima T, Ichinose K, Nakamura H, Tsujino A, Kawakami A, Matsunaka M, Kasagi S, Kawano S, Kumagai S, Ohmura K, Mimori T, Hirano M, Ueno S, Tanaka K, Tanaka M, Toyoshima I, Sugino H, Yamakawa A, Tanaka K, Niikawa N, Furukawa F, Murata S, Eguchi K, Ida H, Yoshiura K (2011) Proteasome assembly defect due to a proteasome subunit beta type 8 (PSMB8) mutation causes the autoinflammatory disorder, Nakajo-Nishimura syndrome. **Proc Natl Acad Sci USA** 108:14914–14919.

Arioglu E, Duncan-Morin J, Sebring N, Rother KI, Gottlieb N, Lieberman J, Herion D, Kleiner DE, Reynolds J, Premkumar A, Sumner AE, Hoofnagle J, Reitman ML, Taylor SI (2000) Efficacy and safety of troglitazone in the treatment of lipodystrophy syndromes. **Ann Intern Med** 133:263–274.

Arboleda H, Quintero L, Yunis E (1997) Wiedemann-Rautenstrauch neonatal progeroid syndrome: report of three new patients. **Journal of Medical Genetics** 34: 433–437.

Auclair M, Vigouroux C, Boccara F, Capel E, Vigerat C, Guerci B, Lascols O, Capeau J, Caron-Debarle M (2013) Peroxisome proliferator-activated receptor- $\gamma$  mutations responsible for lipodystrophy with severe hypertension activate the cellular renin-angiotensin system. **Arterioscler Thromb Vasc Biol** 33: 829-38.

Avila M, Dyment DA, Sagen JV, St-Onge J, Moog U, Chung BHY, Mo S, Mansour S, Albanese A, Garcia S, Martin DL, Lopez AA, and 33 others (2016) Clinical reappraisal of SHORT syndrome with *PIK3R1* mutations: toward recommendation for molecular testing and management. **Clin. Genet.** 89: 501-506.

Avilés-Izquierdo, J.A., Longo-Imedio, M.I., Hernández-Hermosa, J.M., Lázaro-Ochaita, P., 2006. Bilateral localized lipoatrophy secondary to a single intramuscular corticosteroid injection. **Dermatology Online Journal** 12:1.

Barroso I, Gurnell M, Crowley VEF, Agostini M, Schwabel JW, Soos MA, Maslen GL, Williams TDM, Lewis H, Schafer AJ, Chatterjee VKK, O'Rahilly S (1999) Dominant negative mutations in human PPAR- $\gamma$  associated with severe insulin resistance, diabetes mellitus and hypertension. **Nature** 402: 880-883.

Ben Turkia H, Tebib N, Azzouz H, Abdelmoula MS, Ben Chehida A, Hubert P, Douira W, Ben Dridi MF (2009) [Congenital generalized lipodystrophy: a case report with neurological involvement] **Archives de Pédiatrie** 16: 27-31



Ben Yaou R, Navarro C, Quijano-Roy S, Bertrand AT, Massart C, De Sandre-Giovannoli A, Cadiñanos J, Mamchaoui K, Butler-Browne G, Estournet B, Richard P, Barois A, Lévy N, Bonne G (2011) Type B mandibuloacral dysplasia with congenital myopathy due to homozygous ZMPSTE24 missense mutation. **Eur J Hum Genet** 19: 647-54.

Beltrand J, Lahlou N, Le Charpentier T, Sebag G, Leka S, Polak M, Tubiana-Rufi N, Lacombe D, de Kerdanet M, Huet F, Robert JJ, Chevenne D, Gressens P, Levy-Marchal C (2010) Resistance to leptin-replacement therapy in Berardinelli-Seip congenital lipodystrophy: an immunological origin. **Eur J Endocrinol** 162:1083–1091.

Bertrand AT, Chikhaoui K, Ben Yaou R, Bonne G (2011) [Laminopathies: one gene, several diseases]. **Biol Aujourdhui** 205: 147-62.

Bhayana S, Siu VM, Joubert GI, Clarson CL, Cao H, Hegele RA (2002) Cardiomyopathy in congenital complete lipodystrophy. **Clinical Genetics** 61:283–287.

Bidault G, Vatiez C, Capeau J, Vigouroux C, Bereziat V (2011) *LMNA*-linked lipodystrophies: from altered fat distribution to cellular alterations. **Biochem Soc Trans** 39:1752–1757.

Bidault G, Garcia M, Vantighem MC, Ducluzeau PH, Morichon R, Thiyagarajah K, Moritz S, Capeau J, Vigouroux C, Béréziat V (2013) Lipodystrophy-linked *LMNA* p.R482W mutation induces clinical early atherosclerosis and in vitro endothelial dysfunction. **Arterioscler Thromb Vasc Biol** 33: 2162-71.

Boettcher E, Csako G, Pucino F, Wesley R, Loomba R (2012) Meta-analysis: pioglitazone improves liver histology and fibrosis in patients with non-alcoholic steatohepatitis. **Alimentary pharmacology, therapeutics** 35:66–75.

Bolan C, Oral EA, Gorden P, Taylor S, Reitman SF (2002) Intensive, long-term plasma exchange therapy for severe hypertriglyceridemia in acquired generalized lipodystrophy. **J Clin Endocrinol Metab** 87:380–384.

Bolli GB, Owens DR (2000) Insulin glargine. **Lancet** 356:443–445.

Bonert VS, Kennedy L, Petersenn S, Barkan A, Carmichael J, Melmed S (2008) Lipodystrophy in patients with acromegaly receiving pegvisomant. **J Clin Endocrinol Metab**. 93:3515-8.

Brodell, D.W., Marchese Johnson, S (2014) Use of intralesional poly-L-lactic acid in the treatment of corticosteroid-induced lipodystrophy. **Dermatologic Surgery** 40: 597–599.



Brown RJ, Meehan CA, Gorden P (2015) Leptin Does Not Mediate Hypertension Associated With Human Obesity. **Cell** 162:465– 466.

Brown RJ, Chan JL, Jaffe ES, Cochran E, DePaoli AM, Gautier JF, Goujard C, Vigouroux C, Gorden P (2015) Lymphoma in acquired generalized lipodystrophy. **Leuk Lymphoma**. 57(1):45-50.

Brown RJ, Araújo-Vilar D, Cheung PT, Dunger D, Garg A, Jack M, Mungai L, Oral EA, Patni N, Rother KI, von Schnurbein J, Sorkina E, Stanley T, Vigouroux C, Wabitsch M, Williams R, Yorifuji T (2016) The diagnosis and management of lipodystrophy syndromes: a multi-society practice guideline. **J Clin Endocrinol Metab** 101:4500–4511.

Brown RJ, Meehan CA, Cochran E, Rother KI, Kleiner DE, Walter M, Gorden P (2017) Effects of metreleptin in pediatric patients with lipodystrophy. **J Clin Endocrinol Metab** 102:1511–1519.

Brown RJ, Oral EA, Cochran E, Araújo-Vilar D, Savage DB, Long A, Fine G, Salinardi T, Gorden P. (2018) Long-term effectiveness and safety of metreleptin in the treatment of patients with generalized lipodystrophy. **Endocrine**. 60:479-489.

Cabanillas R, Cadiñanos J, Villameytide JA, Pérez M, Longo J, Richard JM, Alvarez R, Durán NS, Illán R, González DJ, López-Otín C (2011) Néstor- Guillermo progeria syndrome: a novel premature aging condition with early onset and chronic development caused by BANF1 mutations. **Am J Med Genet A** 155A: 2617-25.

Calderoni DR, Ramos TM, de Castro JR, Kharmandayan P (2011) Surgical management of phenotypic alterations related to the Dunnigan variety of familial partial lipodystrophy. **Journal of plastic, reconstructive, aesthetic surgery** 64:1248–1250.

Capel E, Vazier C, Cervera P, Stojkovic T, Disse E, Cottureau AS, Auclair M, Verpont MC, Mosbah H, Gourdy P, Barraud S, Miquel A, Züchner S; MFN2-Study Group, Lascols O, Vigouroux C, Jéru I (2018) *MFN2*-associated lipomatosis: Clinical spectrum and impact on adipose tissue. **J Clin Lipidol** Jul 25. doi: 10.1016/j.jacl.2018.07.009

Carboni N, Brancati F, Cocco E, Solla E, D'Apice MR, Mateddu A, McIntyre A, Fadda E, Mura M, Lattanzi G, Piras R, Maioli MA, Marrosu G, Novelli G, Marrosu MG, Hegele R (2014) A partial lipodystrophy associated with muscular dystrophy of unknown genetic origin. **Muscle Nerve** 49: 928-930.

Carrero D, Soria-Valles C, López-Otín C (2016) Hallmarks of progeroid syndromes: lessons from mice and reprogrammed cells. **Dis Model Mech** 9: 719-35.



Casey SP, Lokan J, Testro A, Farquharson S, Connelly A, Proietto J, Angus PW (2013) Post-liver transplant leptin results in resolution of severe recurrence of lipodystrophy-associated nonalcoholic steatohepatitis. **American Journal of Transplantation** 13:3031–3034.

Catapano AL, Chapman J, Wiklund O, Taskinen MR (2011) The new joint EAS/ESC guidelines for the management of dyslipidaemias. **Atherosclerosis** 217:1.

Caux F, Dubosclard E, Lascols O, Buendia B, Chazouilleres O, Cohen A, Courvalin JC, Laroche L, Capeau J, Vigouroux C, Christin-Maitre S (2003) A new clinical condition linked to a novel mutation in lamins A and C with generalized lipoatrophy, insulin-resistant diabetes, disseminated leukomelanodermic papules, liver steatosis, and cardiomyopathy. **J Clin Endocrinol Metab** 88:1006–1013.

Chan JL, Lutz K, Cochran E, Huang W, Peters Y, Weyer C, Gorden P (2011) Clinical effects of long-term metreleptin treatment in patients with lipodystrophy. **Endocr Pract** 17:922–932.

Chan JL, Koda J, Heilig JS, Cochran EK, Gorden P, Oral EA, Brown RJ (2016) Immunogenicity associated with metreleptin treatment in patients with obesity or lipodystrophy. **Clin Endocrinol (Oxf)** 85:137-49.

Chong AY, Lupsa BC, Cochran EK, Gorden P (2010) Efficacy of leptin therapy in the different forms of human lipodystrophy. **Diabetologia** 53:27–35.

Chiquette E, Oral EA, Garg A, Araújo-Vilar D, Dhankhar P (2017) Estimating the prevalence of generalized and partial lipodystrophy: findings and challenges. **Diabetes Metab Syndr Obes** 10:375–383.

Conneely KN, Capell BC, Erdos MR, Sebastiani P, Solovieff N, Swift AJ, Baldwin CT, Budagov T, Barzilai N, Atzmon G, Puca AA, Perls TT, Geesaman BJ, Boehnke M, Collins FS (2012) Human longevity and common variations in the LMNA gene: a meta-analysis. **Aging Cell** 11: 475-81.

Corvillo F, Aparicio V, López-Lera A, Garrido S, Araújo-Vilar D, de Miguel MP, López-Trascasa M. (2018) Autoantibodies against perilipin 1 as a cause of acquired generalized lipodystrophy. **Frontiers in Immunology** 19;9:2142. doi: 10.3389/fimmu.2018.02142.

Corredera C, Iglesias M, Hernández-Martín A, Colmenero I, Dilme E, Torrelo A (2011) Annular lipoatrophic panniculitis of the ankles. **Pediatric Dermatology** 28: 146–148.

Csoka AB, Cao H, Sammak PJ, Constantinescu D, Schatten GP, Hegele RA (2004) Novel lamin A/C gene (LMNA) mutations in atypical progeroid syndromes. **J Med Genet** 41: 304-8.



Debray FG, Baguette C, Colinet S, Van Maldergem L, Verellen-Dumouin C (2013) Early infantile cardiomyopathy and liver disease: a multisystemic disorder caused by congenital lipodystrophy. **Molecular genetics and metabolism** 109:227–229.

Decaudain A, Vantyghe MC, Guerci B, Hecart AC, Auclair M, Reznik Y, Narbonne H, Ducluzeau PH, Donadille B, Lebbe C, Bereziat V, Capeau J, Lascols O, Vigouroux C (2007) New metabolic phenotypes in laminopathies: *LMNA* mutations in patients with severe metabolic syndrome. **J Clin Endocrinol Metab** 92:4835–4844.

Di Gregorio C, D'Arpa S (2016) Therapeutic Use of Hyaluronic Acid Fillers in the Treatment of Corticosteroid-Induced Skin and Subcutaneous Atrophy. **Dermatol Surg**. 42:1307-1310.

Diker-Cohen T, Cochran E, Gorden P, Brown RJ (2015) Partial and generalized lipodystrophy: comparison of baseline characteristics and response to metreleptin. **J Clin Endocrinol Metab** 100:1802–1810.

Doubaj Y, De Sandre-Giovannoli A, Vera EV, Navarro CL, Elalaoui SC, Tajir M, Lévy N, Sefiani A (2012) An inherited *LMNA* gene mutation in atypical Progeria syndrome. **Am J Med Genet A** 158A: 2881-7.

Dyment DA, Gibson WT, Huang L, Bassyouni H, Hegele RA, Innes AM (2014) Biallelic mutations at *PPARG* cause a congenital, generalized lipodystrophy similar to the Berardinelli-Seip syndrome. **Eur J Med Genet** 57:524–526.

Eberting CL, Javor E, Gorden P, Turner ML, Cowen EW (2005) Insulin resistance, acanthosis nigricans, and hypertriglyceridemia. **J Am Acad Dermatol** 52:341–344.

Ebihara K, Kusakabe T, Hirata M, Masuzaki H, Miyanaga F, Kobayashi N, Tanaka T, Chusho H, Miyazawa T, Hayashi T, Hosoda K, Ogawa Y, DePaoli AM, Fukushima M, Nakao K (2007) Efficacy and safety of leptin-replacement therapy and possible mechanisms of leptin actions in patients with generalized lipodystrophy. **J Clin Endocrinol Metab** 92:532–541.

Ehmke N, Graul-Neumann L, Smorag L, Koenig R, Segebrecht L, Magoulas P, Scaglia F, Kilic E, Hennig AF, Adolphs N, Saha N, Fauler B, and 20 others. (2017) De novo mutations in *SLC25A24* cause a craniosynostosis syndrome with hypertrichosis, progeroid appearance, and mitochondrial dysfunction. **Am J Hum Genet** 101: 833-843.

Ellis NA, Groden J, Ye TZ, Straughen J, Lennon DJ, Ciocci S, Proytcheva M, German J (1995) The Bloom's syndrome gene product is homologous to RecQ helicases. **Cell** 83, 655–666.



Farhan SM, Robinson JF, McIntyre AD, Marrosu MG, Ticca AF, Loddo S, Carboni N, Brancati F, Hegele RA (2014) A novel *LIFE* nonsense mutation found using exome sequencing in sib- lings with late-onset familial partial lipodystrophy. **Can J Cardiol** 30:1649–1654.

Fontaine, G., Farriaux, J.P., Blanckaert, D., and Lefebvre, C. (1977). [A new complex polymalformative syndrome]. **J. Genet. Hum.** 25, 109–119.

Francis GA, Li G, Casey R, Wang J, Cao H, Leff T, Hegele RA (2006) Peroxisomal proliferator activated receptor-gamma deficiency in a Canadian kindred with familial partial lipodystrophy type 3 (FPLD3). **BMC Med Genet** 7: 3.

Freidenberg GR, Cutler DL, Jones MC, Hall B, Mier RJ, Culler F, Jones KL, Lozzio C, Kaufmann S (1992) Severe insulin resistance and diabetes mellitus in mandibuloacral dysplasia. **Am J Dis Child** 146: 93-9.

Garg A, Fleckenstein JL, Peshock RM, Grundy SM (1992) Peculiar distribution of adipose tissue in patients with congenital generalized lipodystrophy. **J Clin Endocrinol Metab** 75:358–361

Garg A (2000) Gender differences in the prevalence of metabolic complications in familial partial lipodystrophy (Dunnigan variety). **J Clin Endocrinol Metab** 85: 1776-82.

Garg A (2004) Acquired and inherited lipodystrophies. **N Engl J Med** 350:1220–1234.  
Garg A, Subramanyam L, Agarwal AK, Simha V, Levine B, D'Apice MR, Novelli G, Crow Y (2009) Atypical progeroid syndrome due to heterozygous missense *LMNA* mutations. **J Clin Endocrinol Metab** 94:, 4971-83.

Garg A, Hernandez MD, Sousa AB, Subramanyam L, Martinez de Villarreal L, dos Santos HG, Barboza O (2010) An autosomal recessive syndrome of joint contractures, muscular atrophy, microcytic anemia, and panniculitis-associated lipodystrophy. **J Clin Endocrinol Metab** 95:E58–E63

Garg A (2011) Clinical review#: lipodystrophies: genetic and acquired body fat disorders. **J Clin Endocrinol Metab** 96:3313–3325

Garg A (2011) Clinical review#: lipodystrophies: genetic and acquired body fat disorders. **J Clin Endocrinol Metab** 96:3313–3325.

Garg A, Kircher M, Del Campo M, Amato RS, Agarwal AK (2015) Whole exome sequencing identifies de novo heterozygous *CAV1* mutations associated with a novel neonatal onset lipodystrophy syndrome. **American Journal of Medical Genetics Part A** 167A: 1796–1806.





Garg A, Sankella S, Xing C, Agarwal AK (2016) Whole-exome sequencing identifies *ADRA2A* mutation in atypical familial partial lipodystrophy. **JCI Insight** 16;1(9). pii: e86870.

Giralt M, Villarroya F, Araújo-Vilar D (2017) Lipodystrophy. **Reference Module in Biomedical Research** DOI: 10.1016/B978-0-12-801238-3.65165-6

Gandotra S, Le Dour C, Bottomley W, Cervera P, Giral P, Reznik Y, Charpentier G, Auclair M, Delepine M, Barroso I, Semple RK, Lathrop M, Lascols O, Capeau J, O'Rahilly S, Magre J, Savage DB, Vigouroux C (2011) Perilipin deficiency and autosomal dominant partial lipodystrophy. **N Engl J Med** 364:740–748.

Ghaleiha A, Rasa SM, Nikoo M, Farokhnia M, Mohammadi MR, Akhondzadeh S (2015) A pilot double-blind placebo-controlled trial of pioglitazone as adjunctive treatment to risperidone: Effects on aberrant behavior in children with autism. **Psychiatry Res** 229:181-7.

Gibbons RJ, Smith S, Antman E, American College of C, American Heart A (2003) American College of Cardiology/American Heart Association clinical practice guidelines: Part I: where do they come from? **Circulation** 107:2979 –2986.

Glueck CJ, Mellies MJ, Tsang RC, Kashyap ML, Steiner PM (1977) Familial hypertriglyceridemia in children: dietary management. **Pediatric Research** 11:953–957.

Gorlin RJ, Cervenka J, Moller K, Horrobin M, Witkop J (1975) Rieger anomaly and growth retardation (the S-H-O-R-T syndrome). In: Bergsma, D. (Ed.), **Malformation syndromes. Excerpta Medica for the National Foundation**. March of Dimes, New York, pp. 46–48. BD:OAS XI(2).

Goto M, Miller RW, Ishikawa Y, Sugano H (1996) Excess of rare cancers in Werner syndrome (adult progeria). **Cancer Epidemiology, Biomarkers and Prevention** 5: 239–246.

Graivier MH, Bass LS, Busso M, Jasin ME, Narins RS, Tzikas TL (2007) Calcium hydroxylapatite (Radiessse) for correction of the mid- and lower face: consensus recommendations. **Plastic and reconstructive surgery** 120:55S–66S.

Graul-Neumann LM, Kienitz T, Robinson PN, Baasanjav S, Karow B, Gillissen-Kaesbach G, Fahsold R, Schmidt H, Hoffmann K, Passarge E (2010) Marfan syndrome with neonatal progeroid syndrome-like lipodystrophy associated with a novel frameshift mutation at the 3' terminus of the *FBN1*-gene. **Am J Med Genet A** 152A: 2749-55.



Guglielmi V, D'Adamo M, D'Apice MR, Bellia A, Lauro D, Federici M, Lauro R, Novelli G, Sbraccia P (2010) Elbow deformities in a patient with mandibuloacral dysplasia type A. **Am J Med Genet A** 152A: 2711-3.

Guillén-Navarro E, Sanchez-Iglesias S, Domingo-Jimenez R, Victoria B, Ruiz-Riquelme A, Rabano A, Loidi L, Beiras A, Gonzalez-Mendez B, Ramos A, Lopez-Gonzalez V, Ballista-Martinez MJ, Garrido-Pumar M, Aguiar P, Ruibal A, Requena JR, Araujo-Vilar D (2013) A new seipin-associated neurodegenerative syndrome. **J Med Genet** 50:401-409.

Guillín-Amarelle C, Sánchez-Iglesias S, Araújo-Vilar D (2015) Uncommon lipodystrophic syndromes. **Medicina Clínica** 144: 80-87.

Guillín-Amarelle C, Sanchez-Iglesias S, Castro-Pais A, Rodriguez-Cañete L, Ordoñez-Mayan L, Pazos M, Gonzalez-Mendez B, Rodriguez-Garcia S, Casanueva FF, Fernandez-Marmiesse A, Araujo-Vilar D (2016) Type 1 familial partial lipodystrophy: understanding the Köbberling syndrome. **Endocrine** 54:411-421

Guillín-Amarelle C, Fernández-Pombo A, Sánchez-Iglesias S, Araújo-Vilar D (2018) Lipodystrophic laminopathies: Diagnostic clues. **Nucleus** 9:249-260.

Guillín-Amarelle C, Sánchez-Iglesias S, Mera A, Pintos E, Castro-Pais A, Rodríguez-Cañete L, Pardo J, Casanueva FF, Araújo-Vilar D (2018) Inflammatory myopathy in the context of an unusual overlapping laminopathy. **Arch Endocrinol Metab** 62:376-382.

Hamidou M, Barrier JH, Planchon B, Raffi F, Grolleau JY (1991) Lipoatrophy of the buttocks after intramuscular injection of adrenal cortex hormones. **La Revue De Medecine Interne** 12: 316.

Haque WA, Shimomura I, Matsuzawa Y, Garg A (2002) Serum adiponectin and leptin levels in patients with lipodystrophies. **J Clin Endocrinol Metab** 87:2395.

Hayashi YK, Matsuda C, Ogawa M, Goto K, Tominaga K, Mitsuhashi S, Park YE, Nonaka I, Hino-Fukuyo N, Haginoya K, Sugano H, Nishino I (2009) Human PTRF mutations cause secondary deficiency of caveolins resulting in muscular dystrophy with generalized lipodystrophy. **J Clin Invest** 119:2623-2633.

Hegele RA (2001) Premature atherosclerosis associated with monogenic insulin resistance. **Circulation** 103: 2225-9.

Hegele RA, Ur E, Ransom TP, Cao H (2006) A frameshift mutation in peroxisome-proliferator-activated receptor-gamma in familial partial lipodystrophy subtype 3 (FPLD3; MIM 604367). **Clin Genet** 70: 360-2.



Hegele RA, Joy TR, Al-Attar SA, Rutt BK (2007) Thematic review series: adipocyte biology. Lipodystrophies: windows on adipose biology and metabolism. **Journal of Lipid Research** 48: 1433–1444.

Heidemann LN, Thomsen JB, Sørensen JA (2016) Barraquer-Simons syndrome: a unique patient's perspective on diagnosis, disease progression and recontouring treatment. **BMJ Case Rep.** 11; doi: 10.1136/bcr-2016-21613.

Hennekam RC (2006) Hutchinson-Gilford progeria syndrome: review of the phenotype. **Am J Med Genet A** 140:2603–2624.

Henning KA, Li L, Iyer N, McDaniel LD, Reagan MS, Legerski R, Schultz R., Stefanini M, Lehmann AR, Mayne LV, Friedberg EC (1995) The Cockayne syndrome group A gene encodes a WD repeat protein that interacts with CSB protein and a subunit of RNA polymerase II TFIIH. **Cell** 82: 555-564.

Herane MI, Urbina F, Sudy E (2007) Lipoatrophia semicircularis: a compressive lipoatrophy consecutive to persistent mechanical pressure. **Journal of Dermatology** 34: 390–393.

Hodak E, David M, Sandbank M (1990) Semicircular lipoatrophy—a pressure-induced lipoatrophy? **Clinical and Experimental Dermatology** 15: 464–465.

Hussain I, Garg A (2016) Lipodystrophy syndromes. **Endocrinol Metab Clin N Am** 45:783–797.

Hussain I, Patni N, Ueda M, Sorkina E, Valerio CM, Cochran E, Brown RJ, Peeden J, Tikhonovich Y, Tiulpakov A, Stender SRS, Klouda E, Tayeh MK, Innis JW, Meyer A, Lal P, Godoy-Matos AF, Teles MG, Adams-Huet B, Rader DJ, Hegele RA, Oral EA, Garg A (2018) A novel generalized lipodystrophy-associated progeroid syndrome due to recurrent heterozygous *LMNA* p.T10I mutation. **J Clin Endocrinol Metab.** 103:1005-1014.

Hussein SF, Siddique H, Coates P, Green J (2007) Lipoatrophy is a thing of the past, or is it?. **Diabetic Medicine** 24: 1470–1472.

Imamura S (2012) Lipodystrophia centrifugal abdominalis infantilis: statistical analysis of 168 cases. **Pediatric Dermatology** 29: 437–441.

Javor ED, Moran SA, Young JR, Cochran EK, DePaoli AM, Oral EA, Turman MA, Blackett PR, Savage DB, O'Rahilly S, Balow JE, Gorden P (2004) Proteinuric nephropathy in acquired and congenital generalized lipodystrophy: baseline characteristics and course during recombinant leptin therapy. **J Clin Endocrinol Metab** 89: 3199 –3207.



Javor ED, Ghany MG, Cochran EK, Oral EA, DePaoli AM, Premkumar A, Kleiner DE, Gorden P. (2005) Leptin reverses nonalcoholic steatohepatitis in patients with severe lipodystrophy. **Hepatology** 41:753–760.

Javor ED, Cochran EK, Musso C, Young JR, Depaoli AM, Gorden P (2005) Long-term efficacy of leptin replacement in patients with generalized lipodystrophy. **Diabetes** 54:1994–2002.

Jellinger PS, Smith DA, Mehta AE, Ganda O, Handelsman Y, Rodbard HW, Shepherd MD, Seibel JA, AACE Task Force for Management of Dyslipidemia and Prevention of Atherosclerosis. (2012) American Association of Clinical Endocrinologists' Guidelines for Management of Dyslipidemia and Prevention of Atherosclerosis. **Endocrine practice** 18 Suppl 1:1–78.

Jeru I, Vatier C, Vantyghem MC, Lascols O, Vigouroux C (2017) *LMNA*-associated partial lipodystrophy: anticipation of metabolic complications. **J Med Genet** 54: 413-416.

Ji H, Weatherall P, Adams-Huet B, Garg A (2013) Increased skeletal muscle volume in women with familial partial lipodystrophy, Dunnigan variety. **J Clin Endocrinol Metab** 98: E1410-3.

Karges B, Boehm BO, Karges W (2005) Early hypoglycaemia after accidental intramuscular injection of insulin glargine. **Diabet Med** 22:1444 –1445.

Khalife WI, Mourtada MC, Khalil J (2008) Dilated cardiomyopathy and myocardial infarction secondary to congenital generalized lipodystrophy. **Texas Heart Institute journal** 35:196 –199.

Kluk J, Rustin M, Brogan PA, Omoyinmi E, Rowczenio DM, Willcocks LC, Melly L, Lachmann HJ (2014) Chronic atypical neutrophilic dermatosis with lipodystrophy and elevated temperature syndrome: a report of a novel mutation and review of the literature. **Br J Dermatol** 170:215–217

Kobberling J, Dunnigan MG (1986) Familial partial lipodystrophy: two types of an X linked dominant syndrome, lethal in the hemizygous state. **J Med Genet** 23:120–127.

Koenig R, Brendel L, Fuchs S, (2003) SHORT syndrome. **Clinical Dysmorphology** 12: 45–49.

Kosho T, Takahashi J, Momose T, Nakamura A, Sakurai A, Wada T, Yoshida K, Wakui K, Suzuki T Kasuga K, Nishimura G, Kato H, Fukushima Y (2007) Mandibuloacral dysplasia and a novel *LMNA* mutation in a woman with severe progressive skeletal changes. **Am J Med Genet A** 143A: 2598-603.



Kwapich M, Lacroix D, Espiard S, Ninni S, Brigadeau F, Kouakam C, Degroote P, Laurent JM, Tiffreau V, Jannin A, Humbert L, Ben Hamou A, Tard C, Ben Yaou R, Lamblin N, Klug D, Richard P, Vigouroux C, Bonne G, Vantyghem MC; Diamenord–AEDNL Working Group. 2018 Cardiometabolic assessment of lamin A/C gene mutation carriers: A phenotype-genotype correlation.

*Diabetes Metab.* pii: S1262-3636(18)30177-0. doi: 10.1016/j.diabet.2018.09.006

Lane WS, Cochran EK, Jackson JA, Scism-Bacon JL, Corey IB, Hirsch IB, Skyler JS (2009) High-dose insulin therapy: is it time for U-500 insulin? **Endocrine practice** 15:71–79.

Lavine JE, Schwimmer JB, Van Natta ML, Molleston JP, Murray KF, Rosenthal P, Abrams SH, Scheimann AO, Sanyal AJ, Chalasani N, Tonascia J, Unalp A, Clark JM, Brunt EM, Kleiner DE, Hoofnagle JH, Robuck PR (2011) Nonalcoholic Steatohepatitis Clinical Research N. Effect of vitamin E or metformin for treatment of non- alcoholic fatty liver disease in children and adolescents: the TONIC randomized controlled trial. **JAMA** 305:1659–1668.

Lessel D, Vaz B, Halder S, Lockhart PJ, Marinovic-Terzic I, Lopez-Mosqueda J, Philipp M, Sim JC H, Smith KR, Oehler J, Cabrera E, Freire R, and 25 others (2014) Mutations in SPRTN cause early onset hepatocellular carcinoma, genomic instability and progeroid features. **Nature Genet.** 46: 1239-1244.

Lessel, D.; Hisama, F. M.; Szakszon, K.; Saha, B.; Sanjuanelo, A. B.; Salbert, B. A.; Steele, P. D.; Baldwin, J.; Brown, W. T.; Piussan, C.; Plauchu, H.; Szilvássy, J.; Horkay, E.; Högel, J.; Martin, G. M.; Herr, A. J.; Oshima, J.; Kubisch, C (2015) *POLD1* Germline Mutations in Patients Initially Diagnosed with Werner Syndrome. **Hum Mutat** 36: 1070-9.

Levy, J., Burnett, M.E., Magro, C.M. (2017) Lipophagic panniculitis of childhood: a case report and comprehensive review of the literature. **American Journal of Dermatopathology** 39: 217–224.

Licht, C. L., Stevnsner, T., Bohr, V. A. (2003) Cockayne syndrome group B cellular and biochemical functions. **Am. J. Hum. Genet.** 73: 1217-1239.

Lima JG, Nobrega LH, de Lima NN, do Nascimento Santos MG, Baracho MF, Jeronimo SM (2016) Clinical and laboratory data of a large series of patients with congenital generalized lipodystrophy. **Diabetol Metab Syndr** 8:23.

Linares-García, R., Cuerda-Galindo, E., Bargaño, J.R., Naranjo Garcia P, Vogel-frang-Garncarz D, Palomar-Gallego MA (2015) Semicircular lipoatrophy: an electrostatic hypothesis. **Dermatology** 230: 222–227.



Lotta LA, Gulati P, Day FR, Payne F, Ongen H, van de Bunt M, Gaulton KJ, Eicher JD, Sharp SJ, Luan J, De Lucia Rolfe E, Stewart ID, Wheeler E, Willems SM, Adams C, Yaghootkar H, Consortium EP-I, Cambridge FC, Forouhi NG, Khaw KT, Johnson AD, Semple RK, Frayling T, Perry JR, Dermitzakis E, McCarthy MI, Barroso I, Wareham NJ, Savage DB, Langenberg C, O'Rahilly S, Scott RA (2017) Integrative genomic analysis implicates limited peripheral adipose storage capacity in the pathogenesis of human insulin resistance. **Nat Genet** 49:17–26

Lüdtke A, Genschel J, Brabant G, Bauditz J, Taupitz M, Koch M, Wermke W, Worman HJ, Schmidt HH (2005) Hepatic steatosis in Dunnigan-type familial partial lipodystrophy. **Am J Gastroenterol** 100: 2218-24.

Lüdtke A, Boschmann M, Colpe C, Engeli S, Adams F, Birkenfeld AL, Haufe S, Rahn G, Luft FC, Schmidt HH, Jordan J (2012) Thiazolidinedione response in familial lipodystrophy patients with LMNA mutations: a case series. **Hormone and metabolic research**. 44:306 –311

Lungu AO, Zadeh ES, Goodling A, Cochran E, Gorden P. (2012) Insulin resistance is a sufficient basis for hyperandrogenism in lipodystrophic women with polycystic ovarian syndrome. **J Clin Endocrinol Metab** 97:563–567.

Lupsa BC, Sachdev V, Lungu AO, Rosing DR, Gorden P. (2010) Cardiomyopathy in congenital and acquired generalized lipodystrophy: a clinical assessment. **Medicine (Baltimore)** 89:245–250.

Masotti, A., Uva, P., Davis-Keppen, L., Basel-Vanagaite, L., Cohen, L., Pisaneschi, E., Celluzzi, A., Bencivenga, P., Fang, M., Tian, M., Xu, X., Cappa, M., Dallapiccola, B. (2015) Keppen-Lubinsky syndrome is caused by mutations in the inwardly rectifying K<sup>+</sup> channel encoded by *KCNJ6*. **Am. J. Hum. Genet.** 96: 295-300.

Mazereeuw-Hautier, J.; Wilson, L. C.; Mohammed, S.; Smallwood, D.; Shackleton, S.; Atherton, D. J.; Harper, J. I. (2007) Hutchinson-Gilford progeria syndrome: clinical findings in three patients carrying the G608G mutation in LMNA and review of the literature. **Br J Dermatol** 156: 1308-14.

McPherson, E.; Turner, L.; Zador, I.; Reynolds, K.; Macgregor, D.; Giampietro, P. F. (2009) Ovarian failure and dilated cardiomyopathy due to a novel lamin mutation. **Am J Med Genet A** 149A: 567-72.

McDuffie JR, Riggs PA, Calis KA, Freedman RJ, Oral EA, DePaoli AM, Yanovski JA. (2004) Effects of exogenous leptin on satiety and satiation in patients with lipodystrophy and leptin insufficiency. **J Clin Endocrinol Metab** 89:4258 – 4263.



Meehan CA, Cochran E, Kassai A, Brown RJ, Gorden P (2016) Metreleptin for injection to treat the complications of leptin deficiency in patients with congenital or acquired generalized lipodystrophy. **Expert review of clinical pharmacology** 9:59 – 68.

Merideth, M. A.; Gordon, L. B.; Clauss, S.; Sachdev, V.; Smith, A. C.; Perry, M. B.; Brewer, C. C.; Zalewski, C.; Kim, H. J.; Solomon, B.; Brooks, B. P.; Gerber, L. H.; Turner, M. L.; Domingo, D. L.; Hart, T. C.; Graf, J.; Reynolds, J. C.; Gropman, A.; Yanovski, J. A.; Gerhard-Herman, M.; Collins, F. S.; Nabel, E. G.; Cannon, R. O.; Gahl, W. A.; Introne, W. J (2008) Phenotype and course of Hutchinson-Gilford progeria syndrome. **N Engl J Med** 358: 592-604.

Misra A, Garg A (2003) Clinical features and metabolic derangements in acquired generalized lipodystrophy: case reports and review of the literature. **Medicine (Baltimore)** 82:129–146

Misra A, Peethambaram A, Garg A (2004) Clinical features and metabolic and autoimmune derangements in acquired partial lipodystrophy: report of 35 cases and review of the literature. **Medicine (Baltimore)** 83:18–34.

Mitchel EB, Lavine JE. (2014) Review article: the management of paediatric nonalcoholic fatty liver disease. **Alimentary pharmacology, therapeutics.** 40:1155–1170.

Moran SA, Patten N, Young JR, Cochran E, Sebring N, Reynolds J, Premkumar A, Depaoli AM, Skarulis MC, Oral EA, Gorden P (2004) Changes in body composition in patients with severe lipodystrophy after leptin replacement therapy. **Metabolism** 53:513–519.

Motegi, S.; Yokoyama, Y.; Uchiyama, A.; Ogino, S.; Takeuchi, Y.; Yamada, K.; Hattori, T.; Hashizume, H.; Ishikawa, Y.; Goto, M.; Ishikawa, O (2014) First Japanese case of atypical progeroid syndrome/atypical Werner syndrome with heterozygous *LMNA* mutation. **J Dermatol** 41: 1047-52.

Mory, P. B.; Crispim, F.; Kasamatsu, T.; Gabbay, M. A.; Dib, S. A.; Moisés, R. S (2008) Atypical generalized lipoatrophy and severe insulin resistance due to a heterozygous *LMNA* p.T10I mutation. **Arq Bras Endocrinol Metabol** 52: 1252-6.

Musso C, Cochran E, Javor E, Young J, Depaoli AM, Gorden P. (2005) The long-term effect of recombinant methionyl human leptin therapy on hyperandrogenism and menstrual function in female and pituitary function in male and female hypoleptinemic lipodystrophic patients. **Metabolism** 54:255–263.

Nance MA, Berry SA. (1992) Cockayne syndrome: review of 140 cases. **Am J Med Genet.** 42:68-84.



Ng, D.; Stratakis, C. A. (2000) Premature adrenal cortical dysfunction in mandibuloacral dysplasia: a progeroid-like syndrome. **Am J Med Genet** 95: 293-5.

Novelli, G., Muchir, A., Sanguuolo, F., Helbling-Leclerc A, D'Apice MR, Massart C, Capon F, Sbraccia P, Federici M, Lauro R, Tudisco C, Pallotta R, Scarano G, Dallapiccola B, Merlini L, Bonne G (2002) Mandibuloacral dysplasia is caused by a mutation in LMNA-encoding lamin A/C. **American Journal of Human Genetics** 71: 426–431.

O'Neill, B., Simha, V., Kotha, V., Garg, A ( 2007) Body fat distribution and metabolic variables in patients with neonatal progeroid syndrome. **American Journal of Medical Genetics Part A** 143A: 1421–1430.

Oral EA, Simha V, Ruiz E, Andewelt A, Premkumar A, Snell P, Wagner AJ, DePaoli AM, Reitman ML, Taylor SI, Gorden P, Garg A (2002) Leptin-replacement therapy for lipodystrophy. **N Engl J Med**. 346:570 –578.

Oral EA, Ruiz E, Andewelt A, Sebring N, Wagner AJ, Depaoli AM, Gorden P. (2002) Effect of leptin replacement on pituitary hormone regulation in patients with severe lipodystrophy. **J Clin Endocrinol Metab**. 87:3110 –3117.

Paolacci, S., Bertola, D., Franco, J., Mohammed, S., Tartaglia, M., Wollnik, B., Hennekam, R.C., 2017. Wiedemann-Rautenstrauch syndrome: a phenotype analysis. **American Journal of Medical Genetics Part A** doi: 10.1002/ajmg.a.38246.

Park JY, Chong AY, Cochran EK, Kleiner DE, Haller MJ, Schatz DA, Gorden P. (2008) Type 1 diabetes associated with acquired generalized lipodystrophy and insulin resistance: the effect of long-term leptin therapy. **J Clin Endocrinol Metab**. 93:26 –31.

Passarge E, Robinson PN, Graul-Neumann LM. (2016) Marfanoid-progeroid-lipodystrophy syndrome: a newly recognized fibrillinopathy. **Eur J Hum Genet**. 24:1244-7.

Patni N, Alves C, von Schnurbein J, Wabitsch M, Tannin G, Rakheja D, Garg A (2015) A novel syndrome of generalized lipodystrophy associated with pilocytic astrocytoma. **J Clin Endocrinol Metab** 100:3603–3606.

Payne F, Lim K, Girusse A, Brown RJ, Kory N, Robbins A, Xue Y, Sleigh A, Cochran E, Adams C, Borman AD, Russel-Jones D, Gorden P, Semple RP, Saudek V, O'Rahilly S, Walther TC, Barroso I, Savage DB (2014) Mutations disrupting the Kennedy phosphatidylcholine pathway in humans with congenital lipodystrophy and fatty liver disease. **Proc Natl Acad Sci U S A**. 111:8901-6.





Peteiro-González D, Fernández-Rodríguez B, Cabezas-Agrícola JM, Araújo-Vilar D (2011) Severe localized lipoatrophy related to therapy with insulin analogs in type 1a diabetes mellitus. **Diabetes Res Clin Pract** 91:e61-3.

Peters, M.S., Winkelmann, R.K. (1980) Localized lipoatrophy (atrophic connective tissue disease panniculitis). **Archives of Dermatology** 116: 1363–1368.

Petersen KF, Oral EA, Dufour S, Befroy D, Ariyan C, Yu C, Cline GW, DePaoli AM, Taylor SI, Gorden P, Shulman GI. (2002) Leptin reverses insulin resistance and hepatic steatosis in patients with severe lipodystrophy. **J Clin Invest** 109:1345–1350.

Petty, E.M., Laxova, R., and Wiedemann, H.R. (1990). Previously unrecognized congenital progeroid disorder. **Am. J. Med. Genet.** 35, 383–387.

Pope E, Janson A, Khambalia A, Feldman B (2006) Childhood acquired lipodystrophy: a retrospective study. **J Am Acad Dermatol** 55:947–950.

Puente, X. S.; Quesada, V.; Osorio, F. G.; Cabanillas, R.; Cadiñanos, J.; Fraile, J. M.; Ordóñez, G. R.; Puente, D. A.; Gutiérrez-Fernández, A.; Fanjul-Fernández, M.; Lévy, N.; Freije, J. M.; López-Otín, C (2011) Exome sequencing and functional analysis identifies BANF1 mutation as the cause of a hereditary progeroid syndrome. **Am J Hum Genet** 88: 650-6.

Radermecker, R.P., Piérard, G.E., Scheen, A.J (2007) Lipodystrophy reactions to insulin: effects of continuous insulin infusion and new insulin analogs. **American Journal of Clinical Dermatology** 8: 21–28.

Rajab A, Straub V, McCann LJ, Seelow D, Varon R, Barresi R, Schulze A, Lucke B, Lutzkendorf S, Karbasiyan M, Bachmann S, Spuler S, Schuelke M (2010) Fatal cardiac arrhythmia and long-QT syndrome in a new form of congenital generalized lipodystrophy with muscle rippling (CGL4) due to *PTRF*-CAVIN mutations. **PLoS Genet** 6:e1000874.

Reardon, W., Temple, I. K. (2008) Nephrocalcinosis and disordered calcium metabolism in two children with SHORT syndrome. **Am. J. Med. Genet.** 146A: 1296-1298.

Reinoso-Barbero, L., González-Gómez, M.F., Bélanger-Quintana, D., Piñaga-Solé M, Fernández-Fernández M, Garrido-Astray MC, Capapé-Aguilar A, Mota-Olmeda A, Díaz-Garrido R, Gómez-Gallego F, Bandrés-Moya F, Sanz-González J (2013) Case-control study of semicircular lipoatrophy, a new occupational disease in office workers. **Journal of Occupational Health** 55: 149–157.

Rheuban KS, Blizzard RM, Parker MA, Carter T, Wilson T, Gutgesell HP. (1986) Hypertrophic cardiomyopathy in total lipodystrophy. **The Journal of Pediatrics** 109:301–302.



Robbins DC, Danforth E, Jr., Horton ES, Burse RL, Goldman RF, Sims EA. (1979) The effect of diet on thermogenesis in acquired lipodystrophy. **Metabolism** 28:908–916.

Rocha N, Bulger DA, Frontini A, Titheradge H, Gribsholt SB, Knox R, Page M, Harris J, Payne F, Adams C, Sleight A, Crawford J, Gjesing AP, Bork-Jensen J, Pedersen O, Barroso I, Hansen T, Cox H, Reilly M, Rossor A, Brown RJ, Taylor SI, McHale D, Armstrong M, Oral EA, Saudek V, O’Rahilly S, Maher ER, Richelsen B, Savage DB, Semple RK. (2017) Human biallelic MFN2 mutations induce mitochondrial dysfunction, upper body adipose hyperplasia, and suppression of leptin expression. *Elife*. 6. pii: e23813. doi: 10.7554/eLife.23813.

Rockall AG, Sohaib SA, Evans D, Kaltsas G, Isidori AM, Monson JP, Besser GM, Grossman AB, Reznick RH (2003) Computed tomography assessment of fat distribution in male and female patients with Cushing’s syndrome. **Eur J Endocrinol** 149:561-567.

Rubio-Cabezas O, Puri V, Murano I, Saudek V, Semple RK, Dash S, Hyden CS, Bottomley W, Vigouroux C, Magre J, Raymond-Barker P, Murgatroyd PR, Chawla A, Skepper JN, Chatterjee VK, Suliman S, Patch AM, Agarwal AK, Garg A, Barroso I, Cinti S, Czech MP, Argente J, O’Rahilly S, Savage DB (2009) Partial lipodystrophy and insulin resistant diabetes in a patient with a homozygous nonsense mutation in *CIDEA*. **EMBO Mol Med** 1:280–287.

Safar Zadeh E, Lungu AO, Cochran EK, Brown RJ, Ghany MG, Heller T, Kleiner DE, Gorden P. (2013) The liver diseases of lipodystrophy: the long-term effect of leptin treatment. **J Hepatol**. 59:131-137.

Sanyal AJ, Chalasani N, Kowdley KV, McCullough A, Diehl AM, Bass NM, Neuschwander-Tetri BA, Lavine JE, Tonascia J, Unalp A, Van Natta M, Clark J, Brunt EM, Kleiner DE, Hoofnagle JH, Ro buck PR, Nash CRN.(2010) Pioglitazone, vitamin E, or placebo for non-alcoholic steatohepatitis. **N Engl J Med** 362:1675–1685.

Savage DB, Soos MA, Powlson A, O’Rahilly S, McFarlane I, Halsall DJ, Barroso I, Thomas EL, Bell JD, Scobie I, Belchetz PE, Kelly WF, Schafer AJ. (2004) Familial partial lipodystrophy associated with compound heterozygosity for novel mutations in the *LMNA* gene. **Diabetologia** 47:753–756.

Savage DB, Semple RK, Clatworthy MR, Lyons PA, Morgan BP, Cochran EK, Gorden P, Raymond-Barker P, Murgatroyd PR, Adams C, Scobie I, Mufti GJ, Alexander GJ, Thiru S, Murano I, Cinti S, Chaudhry AN, Smith KG, O’Rahilly S (2009) Complement abnormalities in acquired lipodystrophy revisited. **J Clin Endocrinol Metab** 94:10–16.

Sawyer SL, Cheuk-Him Ng A, Innes AM, Wagner JD, Dymont DA, Tetreault M; Care-4Rare Canada Consortium, Majewski J, Boycott KM, Sreaton RA, Nicholson G (2015).



Homozygous mutations in MFN2 cause multiple symmetric lipomatosis associated with neuropathy. **Hum Mol Genet.** 24:5109-14.

Schlogl H, Muller K, Horstmann A, Miehle K, Puschel J, Villringer A, Pleger B, Stumvoll M, Fasshauer M (2016) Leptin substitution in patients with lipodystrophy: neural correlates for long-term success in the normalization of eating behavior. **Diabetes** 65:2179–2186

Shastry, S., Simha, V., Godbole, K., Sbraccia, P., Melancon, S., Yajnik, C. S., Novelli, G., Kroiss, M., Garg, A. (2010) A novel syndrome of mandibular hypoplasia, deafness, and progeroid features associated with lipodystrophy, undescended testes, and male hypogonadism. **J. Clin. Endocr. Metab.** 95: E192-E197.

Shen, L.Y., Edmonson, M.B., Williams, G.P., Gottam CC, Hinshaw MA, Teng JM (2010) Lipoatrophic panniculitis: case report and review of the literature. **Archives of Dermatology** 146, 877–881.

Schrander-Stumpel, C.; Spaepen, A.; Fryns, J. P.; Dumon, J (1992) A severe case of mandibuloacral dysplasia in a girl. **Am J Med Genet** 43: 877-81.

Schwingshandl, J., Mache, C. J., Rath, K., Borckenstein, M. H.(1993) SHORT syndrome and insulin resistance. **Am. J. Med. Genet.** 47: 907-909.

Semple RK, Chatterjee VK, O’Rahilly S (2006) PPAR gamma and human metabolic disease. **J Clin Invest** 116:581–589.

Settergren J, Eiermann B, Mannheimer B (2013) Adherence to drug label recommendations for avoiding drug interactions causing statin induced myopathy—a nationwide register study. **PloS one.** 3;8: e69545.

Simha, V.; Garg, A (2002) Body fat distribution and metabolic derangements in patients with familial partial lipodystrophy associated with mandibuloacral dysplasia. **J Clin Endocrinol Metab** 87: 776-85.

Simha V, Garg A (2003) Phenotypic heterogeneity in body fat distribution in patients with congenital generalized lipodystrophy caused by mutations in the *AGPAT2* or seipin genes. **J Clin Endocrinol Metab** 88:5433–5437.

Simha, V.; Agarwal, A. K.; Oral, E. A.; Fryns, J. P.; Garg, A (2003) Genetic and phenotypic heterogeneity in patients with mandibuloacral dysplasia-associated lipodystrophy. **J Clin Endocrinol Metab** 88: 2821-4.

Simha V, Szczepaniak LS, Wagner AJ, DePaoli AM, Garg A. (2003) Effect of leptin replacement on intrahepatic and intramyocellular lipid content in patients with generalized lipodystrophy. **Diabetes Care** 26:30 –35.



Simha V, Subramanyam L, Szczepaniak L, Quittner C, Adams-Huet B, Snell P, Garg A. (2012) Comparison of efficacy and safety of leptin replacement therapy in moderately and severely hypoleptinemic patients with familial partial lipodystrophy of the Dunnigan variety. **J Clin Endocrinol Metab** 97:785–792.

Soria-Valles, C.; Carrero, D.; Gabau, E.; Velasco, G.; Quesada, V.; Bárcena, C.; Moens, M.; Fieggen, K.; Möhrcken, S.; Owens, M.; Puente, D. A.; Asensio, Ó.; Loeys, B.; Pérez, A.; Benoit, V.; Wuyts, W.; Lévy, N.; Hennekam, R. C.; De Sandre-Giovannoli, A.; López-Otín, C., (2016) Novel LMNA mutations cause an aggressive atypical neonatal progeria without progerin accumulation. **J Med Genet** 53:776-785.

Stone NJ, Robinson JG, Lichtenstein AH, Bairey Merz CN, Blum CB, Eckel RH, Goldberg AC, Gordon D, Levy D, Lloyd-Jones DM, McBride P, Schwartz JS, Shero ST, Smith SC, Jr., Watson K, Wilson PW, American College of Cardiology/American Heart Association Task Force on Practice G. 2013 (2014) ACC/AHA guideline on the treatment of blood cholesterol to reduce atherosclerotic cardiovascular risk in adults: a report of the American College of Cardiology/American Heart Association Task Force on Practice Guidelines. **J Am Coll Cardiol** 63:2889–2934.

Subramanyam L, Simha V, Garg A (2010) Overlapping syndrome with familial partial lipodystrophy, Dunnigan variety and cardio- myopathy due to amino-terminal heterozygous missense lamin A/C mutations. **Clin Genet** 78:66–73.

Takenouchi T, Hida M, Sakamoto Y, Torii C, Kosaki R, Takahashi T, Kosaki K. (2013) Severe congenital lipodystrophy and a progeroid appearance: Mutation in the penultimate exon of *FBN1* causing a recognizable phenotype. **Am J Med Genet A** 161A:3057-62

Thauvin-Robinet, C., Auclair, M., Duplomb, L., Caron-Debarle M, Avila M, St-Onge J, Le Merrer M, Le Luyer B, Héron D, Mathieu-Dramard M, Bitoun P, Petit JM, Odent S, Amiel J, Picot D, Carmignac V, Thevenon J, Callier P, Laville M, Reznik Y, Fagour C, Nunes ML, Capeau J, Lascols O, Huet F, Faivre L, Vigouroux C, Rivière JB (2013) *PIK3R1* mutations cause syndromic insulin resistance with lipoatrophy. **American Journal of Human Genetics** 93: 141–149.

Torrelo A, Patel S, Colmenero I, Gurbindo D, Lendinez F, Hernandez A, Lopez-Robledillo JC, Dadban A, Requena L, Paller AS (2010) Chronic atypical neutrophilic dermatosis with lipodystrophy and elevated temperature (CANDLE) syndrome. **J Am Acad Dermatol** 62:489–495.

Vallejo A, Garcia-Ruano AA, Pinilla C, Castellano M, Deleyto E, Perez-Cano R. (2018) Comparing Efficacy and Costs of Four Facial Fillers in Human Immunodeficiency Virus-Associated Lipodystrophy: A Clinical Trial. **Plast Reconstr Surg** 41:613-623.



Van Maldergem L, Magre J, Khallouf TE, Gedde-Dahl T Jr, Del-epine M, Trygstad O, Seemanova E, Stephenson T, Albott CS, Bonnici F, Panz VR, Medina JL, Bogalho P, Huet F, Savasta S, Verloes A, Robert JJ, Loret H, De Kerdanet M, Tubiana-Ru N, Megarbane A, Maassen J, Polak M, Lacombe D, Kahn CR, Silveira EL, D'Abronzio FH, Grigorescu F, Lathrop M, Capeau J, O'Rahilly S (2002) Genotype-phenotype relationships in Berardinelli-Seip congenital lipodystrophy. **J Med Genet** 39:722–733.

Vantyghem MC, Pigny P, Maurage CA, Rouaix-Emery N, Stojkovic T, Cuisset JM, Mil-laire A, Lascols O, Vermersch P, Wemeau JL, Capeau J, Vigouroux C (2004) Patients with familial partial lipodystrophy of the Dunnigan type due to a *LMNA* R482W mutation show muscular and cardiac abnormalities. **J Clin Endocrinol Metab** 89: 5337-46.

Vantyghem MC, Vincent-Desplanques D, Defrance-Faivre F, Capeau J, Fermon C, Valat AS, Lascols O, Hecart AC, Pigny P, Delemer B, Vigouroux C, Wemeau JL (2008) Fertility and obstetrical complications in women with *LMNA*-related familial partial lipodystrophy. **J Clin Endocrinol Metab** 93: 2223-9.

Vantyghem MC, Balavoine AS, Douillard C, Defrance F, Dieudonne L, Mouton F, Le-maire C, Bertrand-Escouffaire N, Bourdelle-Hego MF, Devemy F, Evrard A, Gheerbrand D, Girardot C, Gumuche S, Hober C, Topolinski H, Lamblin B, Mycinski B, Ryndak A, Karrouz W, Duvivier E, Merlen E, Cortet C, Weill J, Lacroix D, Wemeau JL (2012) How to diagnose a lipodystrophy syndrome. **Ann Endocrinol (Paris)** 73:170–189.

Vatier C, Fetita S, Boudou P, Tchankou C, Deville L, Riveline J, Young J, Mathivon L, Travert F, Morin D, Cahen J, Lascols O, Andreelli F, Reznik Y, Mongeois E, Madelaine I, Vantyghem M, Gautier J, Vigouroux C (2016) One-year metreleptin treatment improves insulin secretion in patients with diabetes linked to genetic lipodystrophic syndromes. **Diabetes, obesity, metabolism**. 18:693-7.

Victoria B, Cabezas-Agrícola JM, González-Méndez B, Lattanzi G, Del Coco R, Loidi L, Barreiro F, Calvo C, Lado-Abeal J, Araújo-Vilar D. (2010) Reduced adipogenic gene expression in fibroblasts from a patient with type 2 congenital generalized lipodystrophy. **Diabet Med** 27:1178-87.

Walsh BW, Schiff I, Rosner B, Greenberg L, Ravnkar V, Sacks FM (1991) Effects of postmenopausal estrogen replacement on the concentrations and metabolism of plasma lipoproteins. **N Engl J Med** 325:1196 –1204.

Weedon, M.N., Ellard, S., Prindle, M.J., Caswell R, Lango Allen H, Oram R, Godbole K, Yajnik CS, Sbraccia P, Novelli G, Turnpenny P, McCann E, Goh KJ, Wang Y, Fulford J, McCulloch LJ, Savage DB, O'Rahilly S, Kos K, Loeb LA, Semple RK, Hattersley AT. (2013) An in-frame deletion at the polymerase active site of *POLD1* causes a multisystem disorder with lipodystrophy. **Nature Genetics** 45: 947–950.



Wei, C., Thyagarajan, M.S., Hunt, L.P., Shield JP, Stevens MC, Crowne EC (2015) Reduced insulin sensitivity in childhood survivors of haematopoietic stem cell transplantation is associated with lipodystrophic and sarcopenic phenotypes. **Pediatric Blood and Cancer** 62: 1992–1999.

West RJ, Lloyd JK, Turner WM (1975) Familial insulin-resistant diabetes, multiple somatic anomalies, and pineal hyperplasia. **Arch Dis Child** 50:703–708.

Wilson DE, Chan IF, Stevenson KB, Horton SC, Schipke C. (1983) Eucaloric substitution of medium chain triglycerides for dietary long chain fatty acids in acquired total lipodystrophy: effects on hyperlipoproteinemia and endogenous insulin resistance. **J Clin Endocrinol Metab.** 57:517–523.

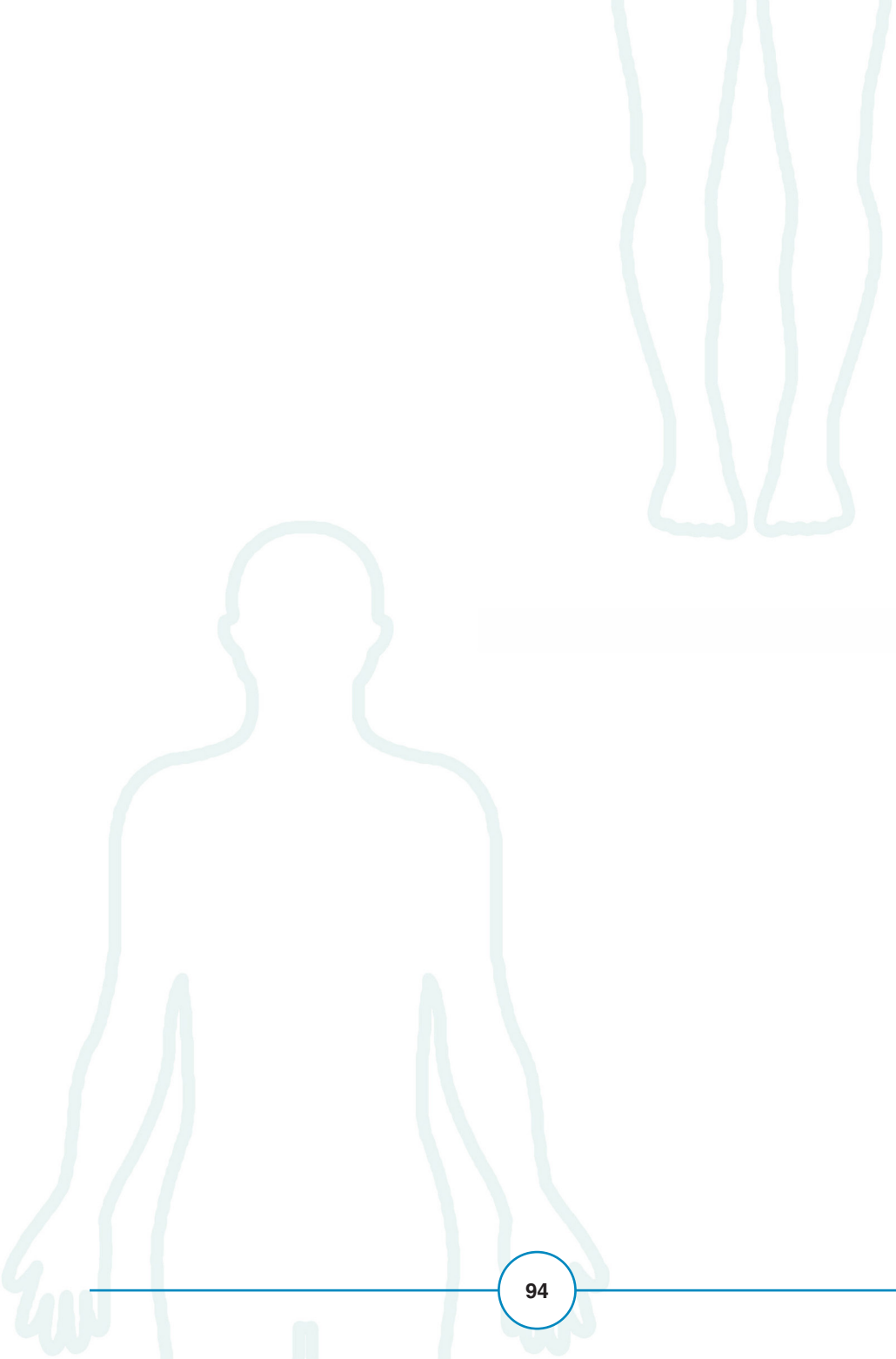
Writzl, K., Maver, A., Kovacic, L. Martinez-Valero, P., Contreras, L., Satrustegui, J., Castori, M., Faivre, L., Lapunzina, P., van Kuilenburg, A. B. P., Radovic, S., Thauvin-Robinet, C., Peterlin, B., del Arco, A., Hennekam, R. C. (2017) De novo mutations in SLC25A24 cause a disorder characterized by early aging, bone dysplasia, characteristic face, and early demise. **Am. J. Hum Genet.** 101: 844-855.

Worman, H.J., Fong, L.G., Muchir, A., Young, S.G (2009) Laminopathies and the long strange trip from basic cell biology to therapy. **Journal of Clinical Investigation** 119: 825–836

Young, L. W.; Radebaugh, J. F.; Rubin, P.; Sensenbrenner, J. A.; Fiorelli, G.; McKusick, V. A (1971) New syndrome manifested by mandibular hypoplasia, acroosteolysis, stiff joints and cutaneous atrophy (mandibuloacral dysplasia) in two unrelated boys. **Birth Defects Orig Artic Ser** 7: 291-7.

Yu, C.E., Oshima, J., Fu, Y.H., Wijsman EM, Hisama F, Alisch R, Matthews S, Nakura J, Miki T, Ouais S, Martin GM, Mulligan J, Schellenberg GD (1996) Positional cloning of the Werner's syndrome gene. **Science** 272, 258–262.

Zolotov S, Xing C, Mahamid R, Shalata A, Sheikh-Ahmad M, Garg A (2017) Homozygous *LIPF* mutation in siblings with multiple symmetric lipomatosis, partial lipodystrophy, and myopathy. **Am J Med Genet A** 173:190–194.





Asociación Internacional de Familiares y Afectados de Lipodistrofias  
[www.aelip.org](http://www.aelip.org)